

Salivary Gland Carcinomas

Recommendations from the society for diagnosis and therapy of
haematological and oncological diseases

Publisher

DGHO Deutsche Gesellschaft für Hämatologie und
Medizinische Onkologie e.V.
Bauhofstr. 12
D-10117 Berlin

Executive chairwoman: Prof. Dr. med. Claudia Baldus

Phone: +49 (0)30 27 87 60 89 - 0

info@dgho.de

www.dgho.de

Contact person

Prof. Dr. med. Bernhard Wörmann
Medical superintendent

Source

www.onkopedia-guidelines.info

The information of the DGHO Onkopedia Web Site is not intended or implied to be a substitute for professional medical advice or medical care. The advice of a medical professional should always be sought prior to commencing any form of medical treatment. To this end, all component information contained within the web site is done so for solely educational purposes. DGHO Deutsche Gesellschaft für Hämatologie und Onkologie and all of its staff, agents and members disclaim any and all warranties and representations with regards to the information contained on the DGHO Web Site. This includes any implied warranties and conditions that may be derived from the aforementioned web site information.

Table of contents

1 Summary	3
2 Basics	3
2.1 Definition and basic information	3
2.2 Epidemiology	3
2.3 Pathogenesis.....	6
2.4 Risk factors	6
3 Prevention and early detection	6
3.1 Prevention.....	6
3.2 Early detection.....	7
4 Clinical characteristics	7
5 Diagnosis	7
5.1 Diagnostic procedures	7
5.1.1 Imaging.....	7
5.1.2 Fine needle aspiration cytology, core needle biopsy and excisional biopsy.....	9
5.1.3 Intraoperative frozen section	9
5.2 Classification.....	10
5.2.1 Staging	10
5.2.2 Histology.....	12
5.2.3 Immunohistology	12
5.2.4 Molecular pathology	13
6 Therapy	13
6.1 Surgery of the primary tumor	14
6.2 Surgery of soft tissues of the neck: neck dissection	15
6.3 Postoperative radiotherapy.....	15
6.4 Adjuvant systemic therapy	16
6.5 Definitive radiotherapy or radiochemotherapy.....	17
6.6 Therapy with non-curative intent: systemic treatment.....	17
6.7 Treatment of local recurrence and distant metastases as a relapse of salivary gland carcinoma	22
6.8 Special situation: salivary gland carcinomas in children.....	22
6.9 Systemic tumor therapy	22
6.9.1 Agents used for systemic tumor therapy (alphabetical)	22
6.9.1.1 Abiraterone acetate	22
6.9.1.2 Axitinib.....	23
6.9.1.3 Avelumab.....	23
6.9.1.4 Bicalutamide	23

6.9.1.5 Cabozantinib.....	24
6.9.1.6 Carboplatin	25
6.9.1.7 Cetuximab	25
6.9.1.8 Cisplatin.....	25
6.9.1.9 Cyclophosphamide	25
6.9.1.10 Dabrafenib.....	25
6.9.1.11 Docetaxel.....	26
6.9.1.12 Doxorubicin.....	26
6.9.1.13 Entrectinib	26
6.9.1.14 Enzalutamide	27
6.9.1.15 Epirubicin.....	27
6.9.1.16 Goserelin.....	27
6.9.1.17 Larotrectinib	28
6.9.1.18 Lenvatinib	28
6.9.1.19 Leuprorelin.....	28
6.9.1.20 Nivolumab.....	29
6.9.1.21 Paclitaxel.....	29
6.9.1.22 Pembrolizumab	29
6.9.1.23 Pertuzumab.....	30
6.9.1.24 Pralsetinib	30
6.9.1.25 Selpercatinib.....	30
6.9.1.26 Sorafenib	31
6.9.1.27 Trametinib.....	31
6.9.1.28 Trastuzumab	31
6.9.1.29 Trastuzumab emtansine.....	31
6.9.1.30 Trastuzumab deruxtecan (T-DXd)	32
6.9.1.31 Triptorelin.....	32
6.9.1.32 Vinorelbine.....	32
7 Rehabilitation.....	33
8 Follow-up and monitoring	33
9 References	33
10 Active studies.....	42
15 Authors' Affiliations	42
16 Disclosure of Potential Conflicts of Interest	44

Salivary Gland Carcinomas

ICD-10: C07, C08.-

Date of document: May 2024

Compliance rules:

- [Guideline](#)
- [Conflict of interests](#)

Authors: Orlando Guntinas-Lichius, Benedicta Beck-Broichsitter, Thorsten Füreder, Marlen Haderlein, Stephan Ihrler, Gunthard Kissinger, Konrad Klinghammer, Jens-Peter Klußmann, Florian Kocher, Nicolas Mach, Moritz Friedo Meyer, Marc Münster, Timothée Olivier, Philippe Schafhausen, Thomas J. Vogl, Barbara Wollenberg

In cooperation with DEGRO and DGHNO-KHC

1 Summary

Salivary gland carcinomas represent a histologically extremely heterogeneous group of tumors of the major and minor salivary glands in the upper aerodigestive tract. The treatment of carcinomas of the major salivary glands predominantly follows common principles, while the treatment of tumors of the minor salivary glands is based more on the localization and treatment principles for head and neck carcinomas of the same localization. Only carcinomas of the salivary glands are presented in this guideline. Close multidisciplinary cooperation between the involved specialists is an important prerequisite for the optimal treatment of patients with salivary gland carcinomas. A curative therapy approach is pursued for salivary gland carcinomas in both early and locally advanced tumors. The curative treatment of choice is surgery of the primary tumor and, if necessary, of the locoregional lymph node metastases. Definitive radio(chemo)therapy is given to patients who cannot undergo surgery. In high-risk patients, postoperative radiotherapy is carried out. Systemic tumor treatment is reserved for non-curatively treatable patients with distant metastases or recurrent tumors unsuitable for local therapy. In recent years, molecular diagnostics have become increasingly important to facilitate personalized treatment decisions particularly for patients with relapsed or metastatic tumors.

2 Basics

2.1 Definition and basic information

Primary salivary gland carcinomas are epithelial malignancies of the major and minor salivary glands in the upper aerodigestive tract. Salivary gland carcinomas are differentiated according to localization (parotid gland, submandibular gland, lingual gland minor salivary glands) and histology. Secondary salivary gland cancers from other primary malignancies must be distinguished from these; this is particularly important if a squamous cell carcinoma is histologically detected in the parotid gland tumor [1].

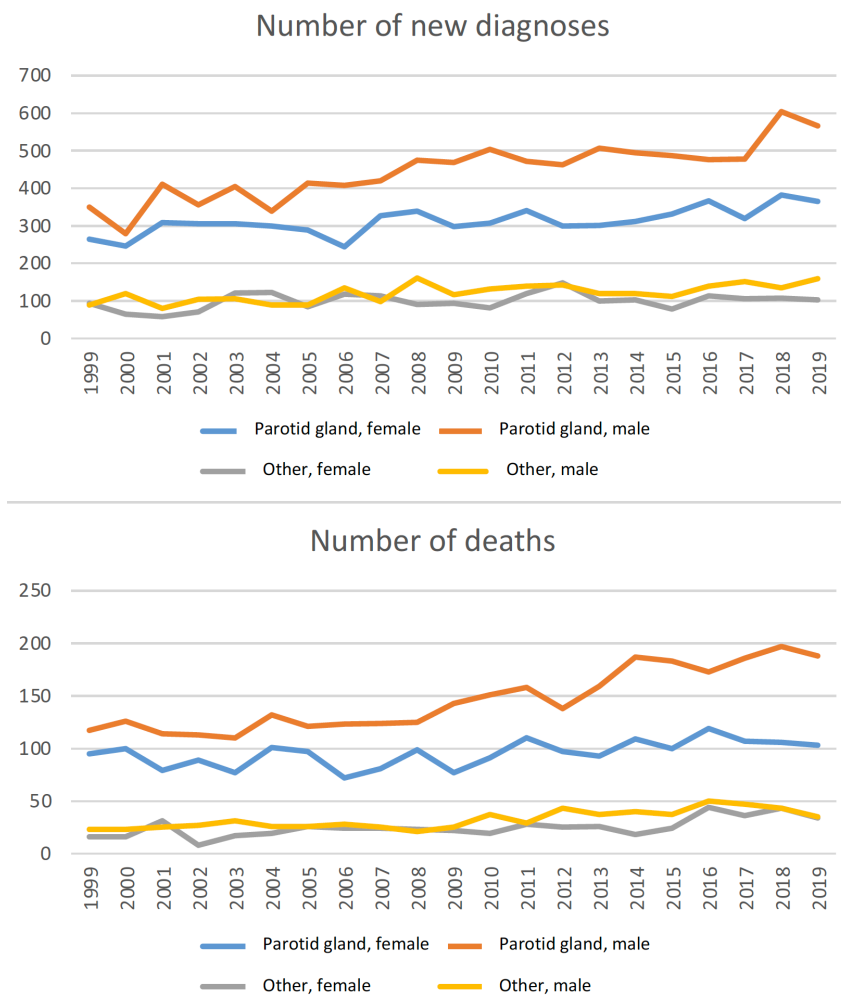
2.2 Epidemiology

Salivary gland carcinomas account for less than 6% of malignant neoplasms in the head and neck region, which are further subdivided into more than 24 histological subtypes according to the 2017 WHO classification of head and neck tumors (more details in section 5.5.2 Histology) [2]. Salivary gland carcinomas are therefore a heterogeneous group of head and neck tumors [3]. They are also tumors with an incidence of 0.5-2 patients per 100,000 people per year [4].

About 20% of all salivary gland tumors are malignant. The smaller the affected salivary gland, the higher the risk that it is a malignant tumor: almost 100% of tumors of the lingual gland and about 60% of small salivary gland tumors are malignant. The prevalence is highest in the 4th to 5th decade of life, with no clear gender predominance worldwide; some histologic subtypes show slight gender differences [5- 7]. About 2% of carcinomas occur in children up to 10 years of age and about 16% of patients are younger than 30 years of age [8, 9].

According to most national population-based studies, no relevant change in incidence rates has been observed in recent years, except for the USA, where an increasing incidence is reported without the causes being identified [6]. The interactive internet-based platform Global Cancer Observatory, which includes the GLOBOCAN data, predicts an increase in salivary gland carcinomas in Germany from 1 patient per 100,000 people per year in 2022 to 1.22 patients per 100,000 people per year in 2045 [10]. In the studies and statistics mentioned, a distinction is made at best between carcinomas of the parotid gland (ICD: C07) and all other carcinomas (ICD: C08). A more detailed analysis of the cancer registry data from North Rhine-Westphalia for 2009-2018 did not show any changes in incidence rates over the past years [6]. In this study, all squamous cell carcinomas were excluded due to the problem of differentiating between primary and secondary carcinomas. In Thuringia, an increase in salivary gland carcinomas was observed for many histological types between 1996 and 2011 (squamous cell carcinomas included) [5]. However, it should be noted that the incidence of cutaneous squamous cell carcinoma in Germany has approximately doubled since the 2000s [11]. It can therefore be assumed that secondary squamous cell carcinomas in the parotid gland have also increased during this period, i.e., metastases into the parotid gland from tumors of other locations were not separated from primary tumors of the parotid gland. This inaccuracy must also be taken into consideration when looking at the current data from the Robert Koch Institute (RKI), as all (primary and secondary) salivary gland malignancies are grouped together here (Figure 1). Between 1999 and 2019, there was a significant increase in malignancies in the parotid gland in men and a slight increase in women in Germany. It can be assumed that this increase in men is not due to primary salivary gland carcinomas, but to secondary tumors, mainly due to metastases from squamous cell carcinomas of the skin. For all other localizations, no changes are seen in the RKI data for either sex. In 2019, 365 women and 566 men were diagnosed with tumors in the parotid gland in Germany. In the other localizations, 102 women and 159 men were affected. The corresponding numbers of death for Germany can also be seen in Figure 1. The increasing incidence of salivary gland tumors is reflected in the number of deaths. In 2019, 103 women and 188 men died from parotid carcinoma. 34 women and 35 men died from salivary gland carcinomas of other locations. Since salivary gland carcinomas of the minor salivary glands in particular are not always registered as salivary gland carcinomas, but instead as head and neck tumors of the corresponding location, an underestimation of the number of cases can be assumed here.

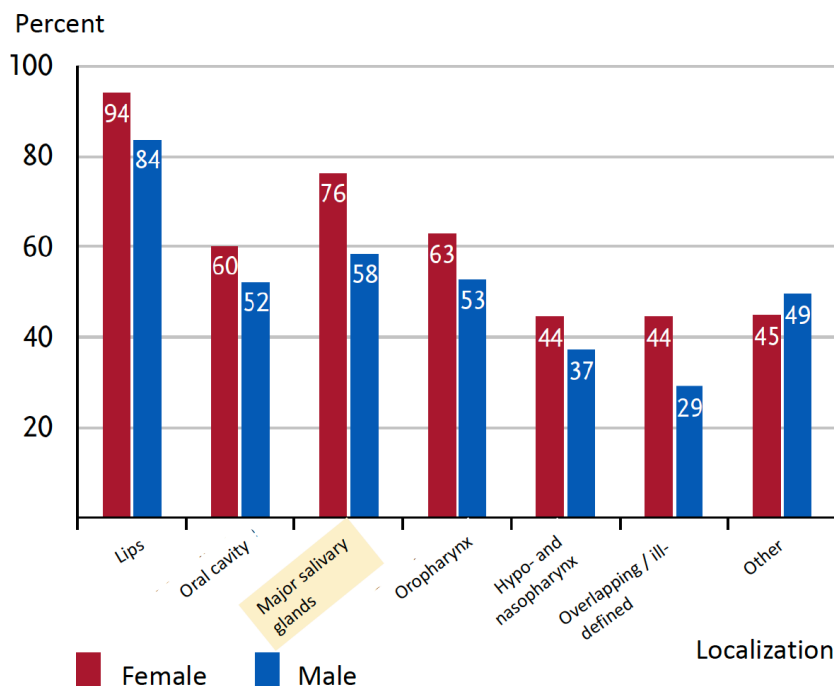
Figure 1: RKI data of new cases and deaths for malignancies of the parotid gland and added up for all other salivary gland tumors, for the years 1999 to 2019*



Legend:
 *(database query at the Center for Cancer Registry Data; accessed: 15 January 2024). As described in the text, methodological inaccuracies must be taken into account when interpreting the figures.

In its report "Cancer in Germany for 2019/2020", the RKI publishes, as before, only a summary of the survival rates of patients with salivary gland carcinomas (Figure 2). According to this, the 5-year survival rate in 2019/2020 was 76% for women and 58% for men [12]. In North Rhine-Westphalia, the average relative 5-year survival rate for all patients between 2009 and 2018 was 69% [6]. In Thuringia, the 5-year and 10-year survival rates between 1999 and 2011 were 60.1% and 48.2% respectively. [5]. The most important prognostic factors are the TNM formula, the histological type and the tumor grading. Carcinomas of the minor salivary glands are rarely considered separately in population-based studies. Five-year survival rates of 76-86% are reported for carcinomas of the minor salivary glands [13]. The risk factors for poorer survival do not differ in comparison to carcinomas of the major salivary glands.

Figure 2: Relative 5-year survival by localization and gender, ICD-10 C00-C14, Germany, 2019-2020; Excerpt from the RKI report "Cancer in Germany for 2019/2020". Relative 5-year survival compared to other head and neck tumors highlighted in yellow [12].



2.3 Pathogenesis

The pathogenesis of salivary gland carcinomas is unclear. Two concepts are currently being discussed: The histogenetic concept assumes that the histologically very different tumor types (see chapter 5.2.2 Histology) develop from the various cell types of salivary gland tissue. The various tumors are thought to evolve from the basal cells or the acinar cells of the glandular acini or the glandular duct sections through pathological replication [14]. According to the morphogenetic concept, tumors develop from stem cells in the gland, and aberrant pathological gene expression influenced by the microenvironment along with epigenetic changes give rise to the various tumor types [14, 15].

2.4 Risk factors

Past exposure to ionizing radiation is the only reliably proven risk factor [16]. This may have been previous radiotherapy in the head and neck area. Exposure to radioactive substances is probably another risk factor. There also appears to be an association with occupation in the rubber manufacturing industry, the hair and cosmetics industry and grain/vegetable cultivation [16- 18]. Lymphoepithelial carcinoma occurs more frequently in patients with AIDS, and the tumors may contain Epstein-Barr virus (EBV) components [19, 20], however, the pathogenic role of HIV or EBV infection is not clear. Overall, the factors mentioned are only responsible for a very small proportion of tumors. In most cases, no cause can be identified. Age is an associated factor, as the incidence increases significantly after the age of 50-60 years.

3 Prevention and early detection

3.1 Prevention

There are no general recommendations for prevention.

3.2 Early detection

There are currently no specific screening instruments for early detection of salivary gland carcinomas. Patients who have undergone radiotherapy to the head and neck area for another malignancy should have their salivary glands examined if they observe any changes.

4 Clinical characteristics

The predominantly non-specific symptoms depend on the location of the salivary gland tumor. In line with other malignant tumors in the head and neck area, symptoms such as weight loss and local pain may occur. The most common symptom is local swelling. In terms of their clinical appearance, malignant tumors often do not differ from the much more common benign tumors here. In the majority of cases, malignant tumors show no typical signs of malignancy [21], which may be invasion of the tumor into the surrounding area, skin infiltration (both of which are associated with poor tumor mobility), rapid growth or facial nerve palsy in tumors of the parotid gland or submandibular gland. In the parotid gland, most salivary gland carcinomas are located in the superficial lobe and invade the deep lobe as they continue to grow. In benign tumors of the minor salivary glands on the hard palate, ulceration (which occurs due to a lack of space for expansion) can falsely simulate a malignant tumor. A salivary gland tumor (especially in the area of the parotid gland) can also appear as an incidentaloma (e.g., during a positron emission tomography-computed tomography [PET-CT] scan ordered for other reasons). Incidentalomas are usually benign salivary gland tumors or may be metastases of other tumors [22].

5 Diagnosis

5.1 Diagnostic procedures

In addition to a detailed medical history, a combination of inspection, palpation and mirror examination is part of the diagnostic standard. In addition, as with all head and neck tumors, performance status, nutritional status, psychosocial history, dental status and an assessment of speech and swallowing function should be obtained. A geriatric assessment is also recommended for patients over 65 years of age [23]. The further procedure depends on the location of the salivary gland tumor. An overview is given in [Table 1](#). In patients with facial nerve palsy, a classification of the extent (grading) and an electrophysiological examination are carried out to objectify the severity of the damage [24].

If the histopathological examination of a tumor of the parotid gland reveals a squamous cell carcinoma, a search of a primary tumor must be performed. Primary squamous cell carcinoma of the parotid gland is extremely rare and is a diagnosis by exclusion [25]. As cutaneous squamous cell carcinomas are the most commonly detected primary tumor localization, a careful examination of the body surface and an evaluation of eventual previously removed skin tumors should be performed. If risk factors for head and neck squamous cell carcinoma are present (see [Onkopedia guideline on head and neck squamous cell carcinoma](#)), panendoscopy should be considered.

5.1.1 Imaging

Ultrasound examination (US) of the soft tissues of the neck is the gold standard for the initial examination of tumors of the large salivary glands. In contrast, tumors of the minor salivary glands can be assessed directly by inspection or endoscopy and are poorly or not at all accessi-

ble for US. Salivary gland tumors, particularly in the superficial lobe of the parotid gland, submandibular gland or sublingual gland, are adequately visualized by US [26].

Magnetic resonance imaging (MRI) using contrast medium (CM) is the diagnostic method of choice for deeper-seated tumors in the parotid gland as well as for tumors that extend into the parapharyngeal space or tumors that cannot be completely visualized by ultrasound. If no MRI with CM is available, computed tomography (CT) may be used. Both US and MRI/CT can also be used for staging of the neck. If a malignancy is already suspected, an MRI with CM is strongly recommended. MRI facilitates the detection of perineural spread, bone invasion and meningeal infiltration. The specificity of US, CT±CM, MRI±CM and also positron emission tomography-computed tomography (PET-CT) are not sufficient to unequivocally prove a malignant tumor. Only histological confirmation (see chapter 5.2.2 Histology) enables a definitive diagnosis. To exclude distant metastases to lungs and/or abdomen, a thoracic and abdominal CT are recommended for patients with advanced tumors (from stage T3 N0 or N1).

In the case of a nodal-positive salivary gland tumor, i.e., also in high-grade subtypes, an FDG-PET-CT scan can be helpful for optimizing treatment planning. The most common localization of distant metastases is the lung. Bone metastases are the second most common site of distant spread [27]. Although the sensitivity of FDG-PET-CT is comparable to conventional CT imaging, a small monocentric study showed a higher specificity for the exclusion of distant metastases [28]. However, this should first be confirmed by more extensive studies before recommendations can be derived from this.

The recommendations for diagnosis and staging are summarized in Table 1.

Table 1: Diagnostic procedures for salivary gland squamous cell carcinoma

Procedure	Comment
Physical examination	Including an examination of the head and neck
Dental status	Relevant if radiotherapy is planned
Laboratory tests	Blood count, liver and kidney function parameters, coagulation, TSH
Ultrasound of the soft tissues of the neck	For the evaluation of a primary tumor of the large head salivary glands and for staging the soft tissues of the neck
Magnetic resonance imaging (MRI) of the soft tissues of the neck with contrast medium (CM)	Tumor staging
Computed tomography (CT) scan of the soft tissues of the neck with CM	If no MRI of the soft tissues of the neck is feasible
Thoracic and abdominal CT scan	Tumor staging for advanced tumors (from cT3/T4 N0 or N1)
Fine needle aspiration cytology (FNAC)	Cytological detection of malignant cells in the tumor
Core needle biopsy (CNB)	Alternative to FNAC
Excisional biopsy	For small tumors of the minor salivary glands
Panendoscopy	In the case of squamous cell carcinoma of the salivary glands, if no cutaneous squamous cell carcinoma of the head and neck is present or has previously been treated
Fluorodeoxyglucose positron emission tomography-computed tomography (FDG-PET-CT)	In selected cases, e.g., additive staging of distant metastatic tumors

5.1.2 Fine needle aspiration cytology, core needle biopsy and excisional biopsy

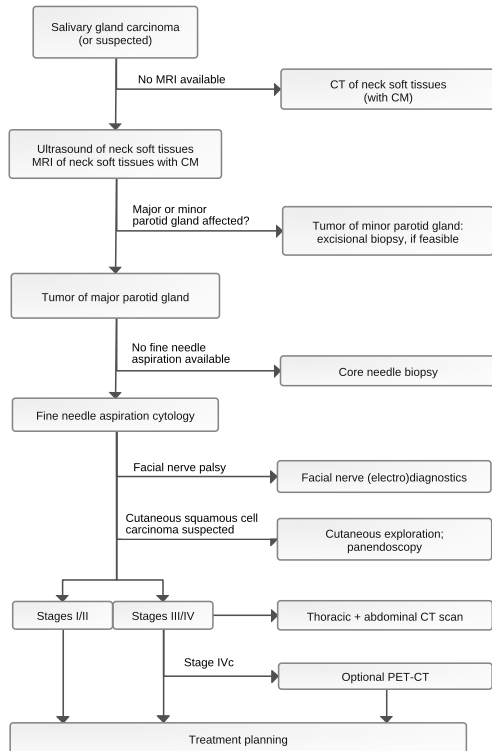
Fine needle aspiration cytology (FNAC) is the standard cytological procedure that can help to detect a malignant salivary gland tumor of the parotid or submandibular gland preoperatively. It is controversially discussed whether the FNAC can distinguish a benign tumor from a highly differentiated salivary gland carcinoma with sufficient certainty. FNAC can also be combined with an US examination, which facilitates the puncture of relevant regions within the tumor. There is no consensus classification system for cytologic evaluation neither internationally nor in Germany. Evaluation using the Milan system is often recommended [29, 30]. FNAC requires the availability of a cytopathologist experienced in the diagnosis of salivary gland carcinomas. An alternative to FNAC is the core needle biopsy (CNB). Performing a CNB under US control also increases the informative value of the results [31]. The tissue sample obtained by CNB allows a histopathological examination. On the other hand, the risk of bleeding is increased with CNB and there is also a theoretical risk of tumor cell spread and injury to the facial nerve [32]. Like FNAC, CNB is well suited to obtaining information about the malignancy of the tumor [33]. To date, there are no prospective studies directly comparing FNAC and CNB in this setting. For tumors of the minor salivary glands, excisional biopsy is recommended, if feasible, as a puncture or incisional biopsy can often lead to substantial histological misinterpretations (including benign versus malignant) [34].

An overview of preoperative diagnostic procedures is summarized in [Figure 3](#).

5.1.3 Intraoperative frozen section

An intraoperative frozen section as part of definitive tumor surgery only plays a role in the detection of a malignant tumor due to its lower reliability in salivary gland carcinomas if the FNAC and CNB have given an unclear result and/or if a very specific clinical situation is present. However, the intraoperative frozen section may increase the reliability of a complete tumor resection (R0 resection), as is also the case with extensive tumors.

Figure 3: Algorithm of the main diagnostic steps.



Legend:

CM = contrast medium; MRI = magnetic resonance imaging; CT = computed tomography; PET = positron emission tomography.

5.2 Classification

5.2.1 Staging

The current TNM classification for tumors of the major head and neck salivary glands is shown in [Table 2](#), and the UICC classification of stages is shown in [Table 3](#). Tumors of the minor salivary glands are subdivided according to the TNM classification for head and neck tumors of the respective region (see [Onkopedia guideline Head and neck squamous cell carcinoma](#)).

The parotid gland contains up to 20 intraparotid lymph nodes. Metastatic involvement of these lymph nodes in carcinomas of the parotid gland has prognostic significance independent of metastatic involvement of the cervical lymph nodes [35]. It is unsatisfactory that the TNM classification still does not provide a clear recommendation as to how intraparotid lymph node metastases should be classified. A non-official recommendation is that these should be included in the N category.

Table 2: TNM classification of malignant tumors (8th edition) for salivary gland carcinomas [36]

T category	
TX	Primary tumor cannot be assessed
T0	No evidence of primary tumor
T1	Tumor ≤ 2 cm in largest dimension, without extraparenchymal extension
T2	Tumor > 2 cm, but ≤ 4 cm in largest dimension, without extraparenchymal extension
T3	Tumor > 4 cm in size and/or with extraparenchymal spread
T4a	Tumor invades skin, lower jaw, external auditory canal, facial nerve
T4b	Tumor invades base of skull, pterygoid process or surrounds the carotid artery
N Category	
NX	Regional lymph nodes cannot be assessed
N0	No regional lymph node metastases
N1	Metastasis in solitary ipsilateral lymph node, ≤ 3 cm in greatest extent, without extranodal spread
N2a	Metastasis in solitary ipsilateral lymph node, > 3 cm but ≤ 6 cm in greatest extent, without extranodal spread
N2b	Metastases in multiple ipsilateral lymph nodes, > 3 cm but ≤ 6 cm in greatest extent, without extranodal spread
N2c	Metastases in bilateral or contralateral lymph nodes, ≤ 6 cm in greatest extent, without extranodal spread
N3a	Metastasis(es) in lymph nodes, > 6 cm in greatest extent, without extranodal spread
N3b	Metastasis(es) in a single or multiple lymph nodes, with extranodal spread
M Category	
M0	No distant metastases
M1	Distant metastasis(es)

Table 3: Stages of carcinomas of the major salivary glands according to the Union internationale contre le cancer (UICC)

Stage	T	N	M
0	Tis	N0	M0
I	T1	N0	M0
II	T2	N0	M0
III	T3	N0	M0
	T1, T2, T3	N1	M0
IVA	T4a	N0, N1	M0
	T1, T2, T3, T4a	N2	M0
IVB	Each T	N3	M0
	T4b	Each N	M0
IVC	Each T	Each N	M1

5.2.2 Histology

Salivary gland carcinomas are assessed according to the current 5th edition of the WHO classification 2022 [37] (Table 4). Some of the new WHO definitions are to be regarded as provisional and some others are considered controversial among pathologists [38]. Genetic aberrations (often translocations) are (in contrast to many other organs) very often entity-specific and can therefore be used as an additional valuable diagnostic criterion when histologic diagnosis is difficult (Table 5). In contrast to other head and neck carcinomas (oral cavity, pharyngeal and laryngeal tumors), the necessity of grading (G) in salivary gland carcinomas is controversially discussed [38]. Only a few of the malignant epithelial tumors show a variable grading from low- to high-grade malignancy. In most cases, the tumors are exclusively low-malignant (e.g., polymorphous adenocarcinoma) or only highly malignant (e.g., salivary duct carcinoma). Unfortunately, the WHO 2022 classification still does not state whether pathologists should use a dichotomous (low versus high malignancy) or a tripartite system (G1, G2, G3) [38].

The histomorphological diagnosis of tumors of small salivary glands is generally much more difficult than for tumors of large salivary glands, and thus leads more frequently to therapeutically relevant misdiagnoses. The most important reasons for this are: incisional biopsies are often performed initially (too small and too superficial), the carcinomas almost always show a high degree of tumor differentiation (without cell atypia), and the special location on the hard palate often leads to ulceration, necrosis and inflammation due to lack of space, which makes diagnosis very difficult. An important recommendation is therefore to always perform a resection (excisional biopsy) instead of a biopsy/incisional biopsy for tumors of the minor salivary glands, if possible [39].

If the pathohistological examination of a tumor of the parotid gland reveals a squamous cell carcinoma, it is most likely a metastasis from a squamous cell carcinoma of a different primary site. Cutaneous squamous cell carcinomas of the head and neck region most frequently metastasize to the parotid gland.

Table 4: Malignant epithelial tumors of the salivary glands according to the WHO classification 2022 [37]

Mucoepidermoid carcinoma	Myoepithelial carcinoma
Adenoid cystic carcinoma	Epithelial-myoepithelial carcinoma
Acinar cell carcinoma	Mucinous adenocarcinoma
Secretory carcinoma	Sclerosing microcystic adenocarcinoma
Microsecretory adenocarcinoma	Carcinoma ex pleomorphic adenoma
Polymorphic adenocarcinoma	Carcinosarcoma
Hyalinizing clear cell carcinoma	Sebaceous adenocarcinoma
Basal cell adenocarcinoma	Lymphoepithelial carcinoma
Intraductal carcinoma	Squamous cell carcinoma
Salivary duct carcinoma	Salivary gland carcinoma, NOS and developing entities
Sialoblastoma	

Legend:

NOS = not otherwise specified

5.2.3 Immunohistology

Given the variety of salivary gland entities with sometimes strongly overlapping histomorphologic features and often difficult differentiation of benign adenomas from highly differentiated

carcinomas, the immunohistologic findings (e.g., cytokeratin subtypes, myoepithelial markers, etc.) can be helpful, but is often substantially limited. More specific immunohistochemical surrogate markers, such as NR4A3 and panTRK, may be diagnostically helpful [40]. For example, positive expression of NR4A3 can support the diagnosis of acinar cell carcinoma, particularly in cases of unusual morphology. And typically, NTRK3-translocated secretory carcinomas show immunohistochemical nuclear expression of panTRK. The overexpression of androgen receptor (AR) and HER2/neu is therapeutically relevant, especially in salivary duct carcinoma, as these alterations can be targeted therapeutically [41]. RAS(Q61R) immunohistochemistry can be used as a surrogate marker to indicate a corresponding HRAS mutation, as is relevant for epithelial-myoeplithelial carcinoma.

5.2.4 Molecular pathology

Molecular typing can be particularly useful for classifying unusual morphological variants (Table 5). In particular, gene fusions generally show a high specificity. The detection of recurrent NTRK or RET gene fusions is not only of diagnostic significance, but can also be used for potential targeted therapy [40].

Table 5: Salivary gland malignancies with diagnostically relevant mutations (in the case of translocations, the most frequent translocation partners) according to Ihrlir et al. [38].

Histological tumor type	Genetic aberrations
Mucoepidermoid carcinoma	<i>CRTC1::MAML2; CRTC3::MAML2</i>
Hyalinizing clear cell carcinoma	<i>EWSR1::ATF1</i>
Adenoid cystic carcinoma	<i>MYB::NFIB; MYBL1::NFIB</i>
Secretory carcinoma	<i>ETV6::NTRK3; ETV6::RET</i>
Carcinoma ex pleomorphic adenoma	<i>PLAG1rearr; HMGA2rearr; ERBB2ampl; MDM2ampl; TP53mut; ARampl</i>
Salivary duct carcinoma	<i>ALKrearr; ERBB2ampl; PTENdel; HRASmut; BRAFmut; ARampl; PIK3CAmut; TP53mut</i>
Polymorphic adenocarcinoma	<i>PRKD1-E710D</i>
Cribriform adenocarcinoma	<i>PRKD1/2/3rearr</i>
Acinar cell carcinoma	<i>NR4A3rearr</i>
Microsecretory adenocarcinoma	<i>MEF2C::SS18</i>
Intraductal carcinoma	<i>NCOA4::RET; TRIM27::RET; HRASmut</i>
Mucinous adenocarcinoma	<i>AKT1-E17K</i>
Epithelial-myoeplithelial carcinoma	<i>HRASmut</i>

6 Therapy

The curative treatment of choice is surgery. Specific factors determine whether postoperative radiotherapy is recommended. Chemotherapy alone has no role in standard curative therapy. In the case of inoperable tumors, radiotherapy is primarily used. Chemotherapy or other systemic tumor therapy is used for inoperable recurrent tumors or distant metastatic tumors, i.e., when local therapy (repeat surgery or radiotherapy) is not an option. Figure 4 provides an algorithm for curative therapy.

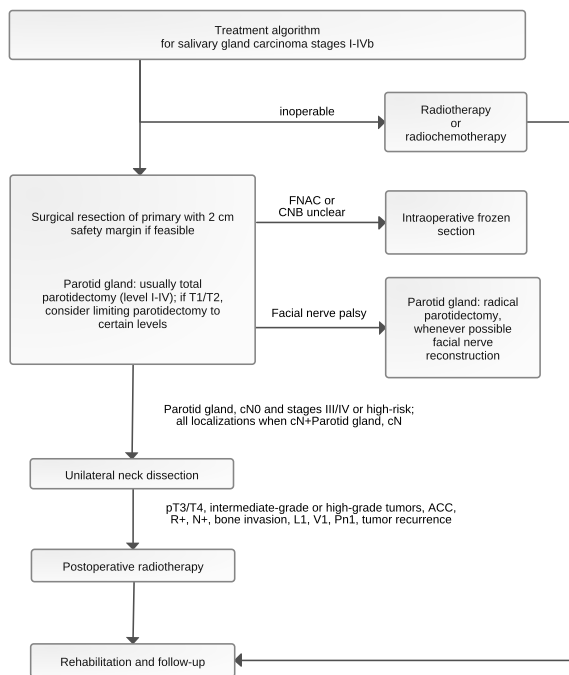
6.1 Surgery of the primary tumor

Surgical removal of a salivary gland carcinoma with tumor-free resection margins is the curative treatment of choice. Tumor resection is performed *en bloc* with a safety margin of 2 cm at best [42]. In the case of tumors of the submandibular gland, resection includes at least the entire gland. For parotid malignancies, the conservative standard is total parotidectomy (parotidectomy level I to IV according to the *European Salivary Gland Society* (ESGS) classification) [26, 43]. Small monocentric case series indicate that lateral parotidectomy (parotidectomy level I/II according to ESGS classification) may also be sufficient for small, low-grade tumors (T1/T2) if tumor-free safety margins are ascertained [44]. The decision to perform a total parotidectomy for diagnosing intraparotid lymph nodes and to initiate adjuvant radiotherapy should be discussed with the patient. However, grading is often only determined after surgery when the final histology is available. If the tumor exceeds the boundaries of the organ, extended surgery is indicated, eventually including reconstructive plastic surgery.

Some salivary gland tumors, especially those of the parotid gland, only turn out to be salivary gland carcinomas after histopathological examination of the resected tissue. These are typically resected under the suspicion of a benign tumor. If only a single-level parotidectomy was performed in such cases, surgical revision to complete the total parotidectomy (level I to IV according to ESGS) is recommended, unless the tumor is a T1/T2 tumor according to the above criteria. It should be noted that surgical revision should be performed as soon as possible if the facial nerve has already been visualized during the primary operation, as the facial nerve is otherwise much more difficult to identify in scars and the risk of postoperative facial nerve palsy increases significantly.

If facial nerve function is normal preoperatively and the facial nerve does not appear to be involved by the tumor during surgery, the facial nerve is preserved. Surgery with magnifying glasses or a surgical microscope and facial nerve monitoring is therefore recommended. Resection of the nerve, i.e., more radical surgery, provides no oncological advantage in terms of survival, but significantly worsens the patient quality of life [45]. If the facial nerve is involved, a radical parotidectomy is performed with resection of the tumor-infiltrated parts of the nerve. In many cases, this enables a one-stage nerve reconstruction with nerve interposition devices [46]. Nerve reconstruction directly following tumor resection produces better functional results than a two-stage procedure. The need for postoperative radiotherapy is no reason not to perform a one-stage reconstruction. If nerve reconstruction is not feasible, or does not appear beneficial due to a life expectancy of < 1 year, or is not preferred by the patient, other measures (dynamic muscle transfer, static sling procedures) can be performed in one or two steps. As the protection of the eye is functionally very important, the implantation of an upper eyelid weight is recommended for the rehabilitation of eye closure after facial nerve resection without or with nerve reconstruction [47].

Figure 4: Algorithm of essential steps for diagnosis and curative therapy.



Legend:

FNAC = fine needle aspiration cytology; CNB = core needle biopsy; ACC = adenoid cystic carcinoma.

6.2 Surgery of soft tissues of the neck: neck dissection

Salivary gland carcinomas show cervical lymph node metastases in 10-40% of cases [48]. A curative neck dissection should be performed in all patients with clinical or radiologic evidence of cervical metastases [49]. There is no standard for the extent of curative neck dissection. Depending on the primary tumor location, this should comprise levels II to IV or I to IV or I to V. The inclusion of level V is controversial, as is the question whether this cannot also be adequately treated electively with adjuvant radiotherapy.

An elective neck dissection should be performed prophylactically in patients with stage III/IV salivary gland carcinoma of the major salivary glands and in high-grade cases (e.g., salivary gland carcinoma NOS, squamous cell carcinoma, undifferentiated carcinoma, high-grade mucoepidermoid carcinoma and carcinoma ex pleomorphic adenoma) [50]. This also applies to adenoid cystic carcinoma, although this tumor type tends to metastasize hematogenously. Neck dissection provides further important prognostic information, such as the presence of extracapsular seeding, which is associated with a poorer prognosis. Elective neck dissection should include neck levels II and III for tumors of the parotid gland and neck levels I to III for tumors of the other major and minor salivary glands. In general, however, elective neck dissection for tumors of the minor salivary glands is controversial [51].

6.3 Postoperative radiotherapy

Postoperative radiotherapy is indicated in the presence of at least one of the following risk factors [52]: advanced T-stage (T3/T4), high-grade tumor, close or positive resection margins (R+), presence of lymph node metastases (N+), perineural sheath infiltration (Pn1), lymph vessel or blood vessel invasion [L1 or V1]) [53, 54]. Surgery alone is therefore sufficient for early T1/T2 tumors without cervical metastasis or any of the other risk factors mentioned [54]. Adenoid cystic carcinoma has a special position: here, adjuvant radiotherapy is indicated also for T1/T2 tumors, in the case of complete resection (R0) and especially in the case of perineural invasion [55].

Postoperative radiotherapy can be administered for intermediate-grade tumors with a close resection margin (1-3 mm) [56- 58].

When defining the target volume, a distinction is made between high-risk clinical target volume (CTV) and elective CTV. The target volume should be defined on the basis of preoperative imaging, histopathological findings, surgical report, and radiation planning CT using intravenous CM. In the case of postoperative residual tumor, MRI imaging should be chosen for radiation planning. The former primary tumor region, the extent of the affected salivary gland, the resection cavity and affected lymph node levels are included in the high-risk CTV.

The elective CTV contains areas with possible microscopic spread, including lymphatic drainage areas or, in the case of perineural sheath infiltration, and the route of the corresponding nerve tracts to the base of the skull. In the case of parotid carcinomas affecting the deep lobe, the infratemporal fossa and the parapharyngeal space are also included [59- 61].

Elective lymphatic drainage irradiation is performed for T3/4 tumors, high-grade tumors and proven lymph node involvement. In the case of lymph node involvement, at least the subsequent lymph node level should also be irradiated. As a rule, the elective lymph drainage areas are irradiated ipsilaterally. In the case of malignancies of the parotid gland and multiple lymph node metastases with extracapsular extension, bilateral irradiation of the lymph drainage areas can be administered [62]. For malignancies of the submandibular gland and minor salivary glands, bilateral irradiation of the lymphatic drainage areas should be applied in the presence of midline infiltration or at least 2 of the following risk factors: pT3/4, proven lymph node metastases, extracapsular extension, lymphatic vessel or vascular invasion. In the case of a cN0 situation, irradiation of the elective lymphatic drainage areas can be omitted in acinar cell carcinoma and low/intermediate grade adenoid cystic carcinoma [63, 64].

The respective planning target volumes (PTV) result from the CTVs, taking into account the individual positioning uncertainty (usually 3-7 mm expansion of the CTV).

In high-risk CTV, a normofractionated dose of at least 60 Gy should be applied and, in the case of a close/positive resection margin and/or perineural sheath infiltration, at least a dose of 64-66 Gy [65- 68]. In elective CTV, a normofractionated dose of 50 Gy is applied.

Highly conformal radiation techniques (VMAT, IMRT) are standard today. In adenoid cystic carcinoma and existing residual tumor postoperatively, heavy ion irradiation may be useful [65].

Additional chemotherapy such as postoperative radiochemotherapy has so far shown no advantages over postoperative radiotherapy in retrospective analyses [69- 71]. However, there are reports indicating that combined cisplatin-containing radiochemotherapy could improve local tumor control, especially in adenoid cystic carcinomas [72, 73]. The results of the prospective randomized trials (RTOG 1008, NCT01220583 and GORTEC 2016-02, NCT02998385) are pending. These studies investigate radiotherapy alone in the adjuvant situation or, in the GORTEC study, in the definitive treatment setting versus combined cisplatin-containing radiochemotherapy. In the adjuvant setting, simultaneous cisplatin-based radiochemotherapy can therefore be given in individual cases.

6.4 Adjuvant systemic therapy

There are currently no prospective studies on adjuvant systemic therapy. Retrospective data indicate a survival benefit from adjuvant therapy with trastuzumab after surgery and radiotherapy in the case of Her2/neu expression DAKO3+ [74]. In addition, according to a retrospective analysis, androgen deprivation using bicalutamide or an LH-RH agonist (goserelin, triptorelin), as monotherapy or in combination, in stage IVa androgen receptor-positive salivary duct carcinoma, given adjuvantly after postoperative radiotherapy over 1-5 years, could provide a sur-

vival benefit over radiotherapy alone [75]. However, there is currently a lack of evidence for this from prospective clinical trials.

6.5 Definitive radiotherapy or radiochemotherapy

Definitive radiotherapy is indicated for inoperable carcinomas, e.g., tumors involving the base of the skull, or in patients with contraindications to surgery.

When defining the target volume, a distinction is made between high-risk CTV and elective CTV. The target volume should be defined based on pre-therapeutic examination and imaging, histopathological findings, a radiation planning CT with intravenous CM and an MRI. The high-risk CTV should include the macroscopic primary tumor, the entire salivary gland and, if present, lymph node metastases. The elective CTV contains areas with possible microscopic spread, including elective draining lymphatic areas or the route of the corresponding nerve tracts to the base of the skull [59, 60].

Elective lymphatic drainage irradiation is performed for T3/T4 tumors, high-grade tumors, adenocarcinomas, mucoepidermoid carcinomas and proven lymph node involvement. In the case of lymph node metastases, at least the subsequent lymph node level should also be irradiated. As a rule, the elective lymph drainage areas are irradiated ipsilaterally. In the case of submandibular and minor salivary gland malignancies, bilateral irradiation of the lymphatic drainage areas should be performed, if midline invasion is documented or if the risk factors cT3/T4 and lymph node metastases are present [64].

The respective planning target volumes (PTV) result from the CTVs, taking into account the individual positioning uncertainty (usually 3-7 mm expansion of the CTV). In high-risk CTV, a normofractionated dose of at least 72 Gy should be applied [76, 77]. In elective CTV, a normofractionated dose of 50 Gy is given. Highly conformal radiation techniques (VMAT, IMRT) are standard today.

As many salivary gland carcinomas grow slowly, there is a relative resistance to radiotherapy, especially in the case of adenoid cystic carcinoma. Radiation qualities with high linear energy transfer properties are therefore of interest for salivary gland carcinomas, such as carbon ions, recently also in combination with proton therapy [78]. Data on particle therapy for salivary gland carcinomas are only available for selected cases in mostly retrospective cohorts [79]. Particle therapy should therefore be evaluated as a possible alternative to irradiation with photons if better dose application can be achieved in the vicinity of critical organs at risk.

Definitive radiochemotherapy may be considered. There are no clear criteria for the use of definitive radiochemotherapy compared to definitive radiotherapy [73, 80]. There is also no standard for the selection of chemotherapeutic agent(s). In most cases, cisplatin-based therapy is used, referring to data on common head and neck tumors [78, 79, 81].

6.6 Therapy with non-curative intent: systemic treatment

There is no standard for the treatment of non-curatively treatable salivary gland carcinomas. The rarity and heterogeneity of salivary gland carcinomas make it difficult to conduct large-scale studies on systemic therapy. Accordingly, no large phase III trial data are available in the recurrent or distant metastatic treatment situation. Recommendations for systemic therapy are therefore primarily based on the results of phase II studies or molecularly stratified basket studies. A number of further phase II trials using new substances are currently underway (overview in: [15, 82, 83]). The majority of the therapies listed here have not been approved for use in salivary gland carcinomas. It is therefore recommended to obtain the consent of the patient's health insurance company before administration.

The course of the disease in the metastatic situation is variable, and a relevant proportion of patients remain asymptomatic for a long time. Accordingly, a watch-and-wait strategy is justified in selected cases (low tumor burden, stable disease, no symptoms). In particular, adenoid cystic carcinomas (especially with an isolated pulmonary metastatic pattern), myoepithelial carcinomas and acinar cell carcinomas may show only a slight growth tendency over a long period of time [84- 86]. This also applies to second-line therapy after failure of first-line therapy.

Systemic therapy based on the treatment protocols for head and neck squamous cell carcinomas (HNSCC) is not recommended, as patients with salivary gland carcinoma were excluded from these studies [87]. In addition, the use of immune checkpoint inhibitors - in contrast to the frequent head and neck tumors - has not yet played a decisive role in salivary gland carcinomas. The immuno-oncological approaches with checkpoint inhibitors have so far not been convincing in most cases of salivary gland carcinomas [88, 89].

In patients with high tumor burden and disease dynamics, systemic therapy with one or more chemotherapeutic agents may be indicated. In an indirect comparison, combination chemotherapies show higher response rates than monochemotherapy. Platinum-based chemotherapy regimens (using cisplatin or carboplatin) are mainly used with dosages derived from the therapeutic principles of systemic therapy for the common HNSCC, including the combination with cyclophosphamide and doxorubicin (CAP regimen), platinum doublet with a taxane (not for adenoid cystic carcinoma) or with vinorelbine. The response rates are 20-60% [90, 91]. The combination of carboplatin and paclitaxel is also used in metastatic salivary duct carcinoma [92]. However, the extrapolation of treatment regimens from HNSCC to salivary gland carcinoma should be made with caution, and the individual subtype of salivary gland carcinoma should be taken into account. For example, the activity of paclitaxel in adenoid cystic carcinoma is very limited and its use is therefore not recommended [93]. In the case of a reduced general condition, monochemotherapy with vinorelbine, cisplatin or epirubicin are possible treatment options [90, 94, 95].

In >95% of cases of secretory salivary gland carcinoma, an *ETV6-NTRK3* gene fusion is detectable. It results in excessive tyrosine kinase activity. This makes targeted therapy possible. The two tyrosine kinase inhibitors entrectinib and larotrectinib are approved for the treatment of *NTRK*-positive tumors and show good efficacy in secretory salivary gland carcinoma [96, 97]. Entrectinib achieved a response rate of 57% in a collective of *NTRK* gene fusion-positive tumor patients. In the subgroup of 7 patients with secretory carcinoma, a response rate of 86% was reported [97]. Immunohistochemical *TRK* expression correlates with *NTRK1* and *NTRK2* fusions, although the specificity appears to be lower in the case of salivary gland carcinomas compared to other solid tumors. RNA-based confirmation of gene fusion is necessary before starting treatment with an *NTRK* inhibitor [98].

Anti-*HER2* therapy should be considered for *HER2*-positive tumors. Up to 30% of mucoepidermoid carcinomas and 40% of salivary duct carcinomas show *HER2* overexpression. Phase II studies show very high response rates to *HER2* blockade in this setting, e.g., with docetaxel plus trastuzumab (response rate up to 70%) or ado-trastuzumab emtansine after trastuzumab failure [99- 101]. The combination of trastuzumab and pertuzumab is a potential option for patients with a contraindication to taxane therapy. According to a subgroup analysis of a basket study, the response rate with trastuzumab and pertuzumab was 60% [102]. The antibody-chemotherapy conjugate (ADC) trastuzumab-deruxtecan represents a new potential treatment option. A response rate of 37% was achieved in a *HER2-positive* patient collective without other treatment alternatives [103]. Among the 19 patients with *HER2*-positive salivary gland carcinoma included in the study, the response rate was 42%. In the meantime, trastuzumab deruxtecan has received tumor diagnostic approval in the USA for *HER2*-positive (IHC3+; immunohistochemically triple positive) tumor diseases without satisfactory treatment alternatives. The decision regarding the extension of the approval by the European Medicines Agency remains to be awaited.

RET gene fusions are a rare driver in non-small cell lung carcinoma, thyroid carcinoma or tumors of the gastrointestinal tract. In salivary duct carcinomas and secretory carcinomas, the corresponding fusions are described in a small, but relevant proportion. The selective *RET* kinase inhibitor selpercatinib was investigated in a tumor-agnostic phase I/II study. Among the four patients with salivary gland carcinoma included in the study, the response rate was 50% [104].

In a large-scale molecular profiling study of salivary gland carcinomas, *BRAF* alterations were detected in 2.7% of all patients [105]. To date, there are case reports in the literature in which clinical activity of corresponding inhibitors (dabrafenib and trametinib) was observed in *BRAF*-altered salivary gland carcinomas [106].

Antiangiogenic substances represent a therapeutic option for adenoid cystic carcinoma. The multi-tyrosine kinase inhibitor lenvatinib was investigated in a phase II trial involving 33 patients with adenoid cystic carcinoma and progression following prior therapy. The response rate with lenvatinib was 15%, and 75% of the group showed stabilization of the disease [107]. The tyrosine kinase inhibitors sorafenib and axitinib were also tested in phase II trials in adenoid cystic carcinoma. A response rate of 16% was reported with sorafenib and 9% with axitinib [108, 109]. It should be noted that disease progression before the start of treatment was not an inclusion criterion in the studies mentioned. In another recent randomized phase II study, axitinib showed a significantly better progression-free survival rate at 6 months (73.0%) than a wait-and-see approach (23.0%) in patients with recurrent or metastatic adenoid cystic carcinoma [110]. The combination of axitinib with the checkpoint inhibitor avelumab was also investigated in relapsed or metastatic adenoid cystic carcinoma and resulted in an 18% response with a progression-free survival of 7.3 months and an overall survival of 16 months in a non-randomized study [111].

In contrast to other salivary gland carcinomas, salivary duct carcinomas very frequently exhibit androgen receptor expression (80%). Androgen deprivation is a possible treatment option as first-line therapy or as second-line therapy in the event of progression after chemotherapy or low disease burden in the case of high nuclear androgen receptor positivity (>70%) [112]. There are reports indicating that patients with androgen receptor-positive salivary duct carcinoma or salivary gland carcinoma NOS benefit from androgen deprivation therapy with leuprorelin or bicalutamide [113, 114]. In a phase II study, the combination of leuprorelin and bicalutamide achieved a response rate of 40% in salivary gland carcinoma [115]. In a castration-resistant situation, the use of bicalutamide plus LHRH agonists was clinically effective according to a phase II study [116]. For second-line therapy, the use of abiraterone should be weighed against enzalutamide or chemotherapy. In a phase II study of 24 patients, abiraterone resulted in disease control in 62% and a median PFS of 3.6 months [116]. Enzalutamide achieved disease control in 67% of study participants, which translated into a median PFS of 5.6 months and overall survival of 17 months [117]. In double *HER2*-positive/androgen receptor-positive salivary duct carcinoma, *HER2* blockade and androgen deprivation therapy can be given sequentially [118]. However, the optimal treatment sequence for these double-positive salivary gland carcinomas has not yet been defined.

Especially before second-line or third-line therapy, it is recommended that patients be presented to a molecular tumor board. The possible targets for a personalized treatment decision are shown in Table 6.

Table 6: Molecular targets for targeted therapy*****

Target	Therapeutic agents*	Histological type
ETV6-NTRK gene fusion	Larotrectinib Entrectinib Selitrectinib	Secretory carcinoma
Androgen receptor	Bicalutamide Leuprorelin Abiraterone acetate	Salivary duct carcinoma Salivary gland carcinoma NOS
HER2/new	Trastuzumab (± pertuzumab) Ado-trastuzumab emtansine	Salivary duct carcinoma Adenocarcinoma**** Mucoepidermoid carcinoma
PI3KCA	Alpelisib	Salivary duct carcinoma Adenocarcinoma****
RET gene fusion	Selpercatinib	Salivary duct carcinoma
BRAF p.V600E	Dabrafenib Trametinib	Salivary duct carcinoma
PD1/PD-L1 + CTLA-4	Nivolumab Pembrolizumab Avelumab Nivolumab + ipilimumab	Unselected or with positive PD-L1 status, TMB/MSI high; the combination mentioned are for all tumors except adenoid cystic carcinoma; possible in combination with VEGFR inhibitor in adenoid cystic carcinoma
VEGFR	Axitinib Lenvatinib Sorafenib	Unselected, but especially for adenoid cystic carcinoma
EGFR	Cetuximab	Unselected
c-MET	Cabozantinib**	Adenoid cystic carcinoma
NOTCH	CB-103 (Limantrafin) Nirogacestat***	Adenoid cystic carcinoma

Legend:

*Most of the drugs are not approved for use in salivary gland carcinomas. Here, consent should be obtained from the patient's health insurance company before administration (see Approval status);

**cave: very toxic; especially wound healing disorders in pre-irradiated areas [120]

***To date, there are no publications on salivary gland carcinoma; proven efficacy in desmoid tumors [119]

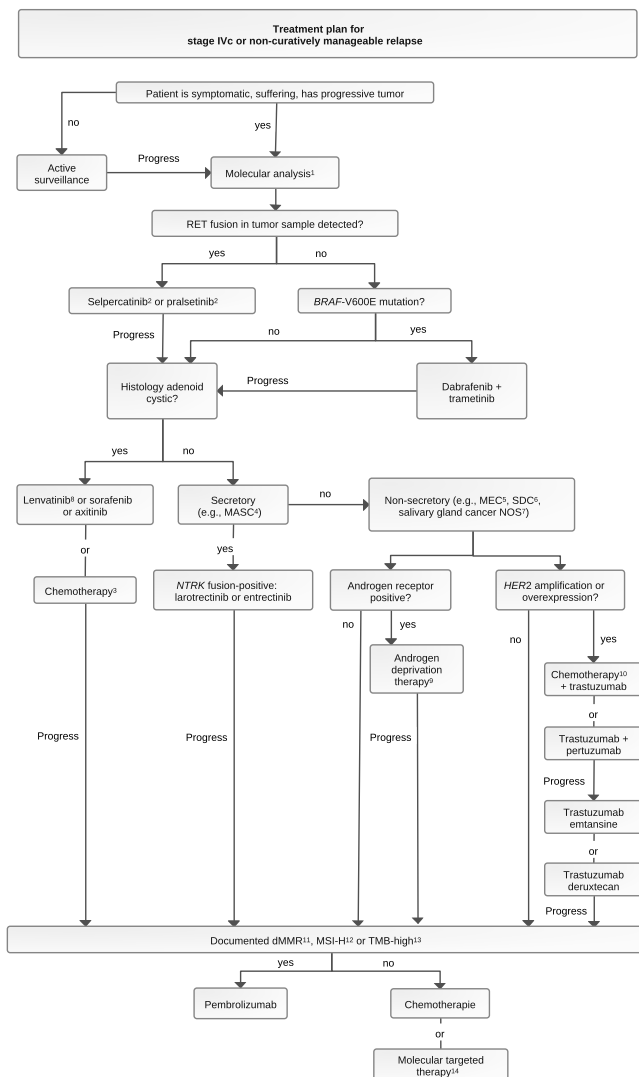
**** The studies partly used an older terminology for the classification of salivary gland tumors

***** after: [82, 83] supplemented by [100, 104, 119, 120]

TMB = Tumor Mutational Burden, MSI = Microsatellite Instability;

Figure 5 shows how molecular testing supports the treatment decision for systemic therapy.

Figure 5: Diagnostic algorithm for systemic therapy taking molecular diagnostics into account. Update and extension of the illustration from: [121].



Legend:

- ¹ early presentation to the molecular tumor board;
- ² approved for non-small cell lung carcinoma and thyroid carcinoma with proven RET alteration;
- ³ preferably cis-/carboplatin plus cyclophosphamide plus doxorubicin (CAP), alternatively cis-/carboplatin plus docetaxel/paclitaxel or plus vinorelbine; in case of severe comorbidity, monotherapy with vinorelbine, cisplatin or epirubicin;
- ⁴ MASC - mammary analogue secretory carcinoma;
- ⁵ MEC - mucoepidermoid carcinoma;
- ⁶ SDC - salivary duct carcinoma;
- ⁷ NOS - not otherwise specified;
- ⁸ preferred option;
- ⁹ leuprorelin or bicalutamide or leuprorelin plus bicalutamide; if indicated, switch to enzalutamide or abiraterone/prednisone;
- ¹⁰ paclitaxel or docetaxel, alternatively carboplatin plus paclitaxel;
- ¹¹ dMMR - mismatch repair deficiency;
- ¹² MSI-H - high microsatellite instability;
- ¹³ TMB-high - tumor mutation burden > 10 mutations per megabase;
- ¹⁴ if a suitable molecular target is available, based on the recommendation of the molecular tumor board;
- ¹⁵ preferred in sequence: first-line with tyrosine kinase inhibitor ± checkpoint inhibitor and chemotherapy for second-line

6.7 Treatment of local recurrence and distant metastases as a relapse of salivary gland carcinoma

Relapse of salivary gland carcinoma is often very aggressive, with a high risk of distant metastases [122]. Salvage surgery is only possible in selected cases. After resection of a locoregional relapse, radiotherapy is indicated postoperatively in non-pre-irradiated patients as in the primary treatment setting (see chapter 6.3.). Radiotherapy should be performed for locally inoperable or incompletely resected locoregional relapses that have not been previously irradiated, and heavy ion irradiation should be considered for adenoid cystic carcinomas. Re-irradiation with heavy ions or highly conformal stereotactic techniques should be considered for pre-irradiated, locally inoperable or incompletely resected relapses [123, 124].

With regard to distant metastases, adenoid cystic carcinoma is a special case: hematogenous metastases occur in 25-50% of patients in the long-term course [125]. Due to the slow growth, patients with adenoid cystic carcinoma can still have a long life expectancy. For this tumor type, resection of lung metastases for local pulmonary control of the disease is therefore also an option [126]. Alternatives to resection of metastases include other local ablative procedures such as radiofrequency ablation or stereotactic radiotherapy [127].

For the use of systemic treatment for recurrent tumors, please refer to chapter 6.6.

6.8 Special situation: salivary gland carcinomas in children

About 5% of all salivary gland tumors affect children [128]. 40-60% of these tumors in children are malignant, i.e., much more common than in adults. Mucoepidermoid carcinoma (45-50%) and acinar cell carcinoma (25-35%) are the most common malignant histologic types in children [9]. The therapeutic principles in children do not differ from that in adults [129]. Surgery is the curative treatment of choice, possibly followed by postoperative radiotherapy (for indications for postoperative radiotherapy, see chapter 6.3.). In children with a pN0 neck, postoperative radiotherapy is generally decided with more restraint. As a rule, postoperative radiotherapy of the soft tissues of the neck is not performed for pN0.

6.9 Systemic tumor therapy

6.9.1 Agents used for systemic tumor therapy (alphabetical)

6.9.1.1 Abiraterone acetate

Abiraterone acetate is an antiandrogen (androgen synthesis inhibitor) that is approved for the antihormonal therapy of prostate cancer. By inhibiting the enzyme CYP17, extragonadal androgen biosynthesis in the tumor and metastases is also inhibited. It is administered in combination with 10 mg prednisone daily. The main side effects are fatigue, hot flashes, edema, hypokalemia and -magnesiumemia and constipation.

Abiraterone is a CYP3A4 substrate, so CYP3A4 inducers accelerate its oxidative metabolism. Concomitant treatment with strong CYP3A4 inducers may reduce the bioavailability of abiraterone and possibly impair its efficacy. The concomitant use of CYP3A4 inhibitors does not affect the plasma levels of abiraterone. Concomitant treatment with abiraterone and [223Ra]radium chloride has been associated with increased bone fractures and deaths, so that concomitant treatment with [223Ra]radium chloride is contraindicated. Androgen deprivation therapy with abiraterone may prolong the QT interval. The risk of ventricular tachycardia is therefore increased under concomitant treatment with drugs that can also prolong the QT interval. Torsade de pointes with symptomatic attacks of dizziness or fainting may occur. In rare

cases, they may progress to ventricular fibrillation and cardiac arrest. Concomitant use with drugs that prolong the QT time should be weighed up with great caution. Abiraterone is a CYP2D6 inhibitor and inhibits the oxidative metabolism of CYP2D6 substrates. Abiraterone may impair the analgesic and antitussive efficacy of codeine and increase the bioavailability of dextromethorphan by approximately 200%. Concomitant treatment with abiraterone may increase the effects of CYP2D6 substrates (ajmaline, amphetamines, dextromethorphan, flecainide, haloperidol, hydromorphone, metoprolol, propafenone, propranolol, risperidone, tramadol, venlafaxine). Simultaneous administration of abiraterone with food increases abiraterone exposure up to 17-fold.

6.9.1.2 Axitinib

Axitinib is a tyrosine kinase inhibitor that selectively inhibits VEGF receptors 1-3. It is approved for second-line treatment of renal cell carcinoma. The main side effects are hypertension, mucositis, weight loss, proteinuria, diarrhea and fatigue.

Axitinib is extensively metabolized in the liver via CYP3A4 and to a lesser extent via CYP1A2 and CYP2C19. Concomitant treatment with strong CYP3A4/5 inducers can reduce the active substance concentrations of axitinib and thus impair its clinical efficacy. Concomitant treatment with strong CYP3A4 enzyme inhibitors may increase the active substance concentrations of axitinib and thus also increase adverse effects. No clinically relevant study results are available on a possible pharmacodynamic enhancement of the side effects of axitinib by other drugs or a possible influence of axitinib on the effect of other drugs. Taking axitinib together with a moderately high-fat meal led to a 10% reduction in bioavailability compared to fasting intake. A high-calorie meal increased bioavailability by 19%. These effects are not considered clinically significant. The concomitant use of strong CYP3A4 inhibitors or inducers with axitinib should be avoided. The consumption of grapefruit, grapefruit-like fruits (e.g., pomelo, bitter orange, clematine) and their preparations should be avoided during the entire treatment with axitinib. If concomitant treatment with axitinib and strong CYP3A4 inhibitors is unavoidable, a reduction in the dose of axitinib to approximately half is recommended. If macrolide antibiotics are indicated, drugs that do not or only slightly inhibit CYP3A4 (e.g., azithromycin) should be preferred. If a strong CYP3A4/5 inducer must be used at the same time, it is recommended to increase the axitinib dose gradually. After discontinuation of the inducer, the axitinib dose must be reduced slowly, as the inducing effects persist beyond discontinuation of the inducer due to the lifespan of the enzymes.

6.9.1.3 Avelumab

Avelumab is a human monoclonal IgG1 antibody from the class of immune checkpoint inhibitors. It binds to [programmed cell death ligand 1](#) (PD-L1) and prevents it from binding to its receptor PD-1. Approved indications include cutaneous Merkel cell carcinoma, renal cell carcinoma and urothelial carcinoma. The most common side effects under palliative combination therapy with axitinib in adenoid cystic salivary gland carcinoma [111] were fatigue, diarrhea, hypertension, nausea, weight loss, constipation and, as presumably autoimmune-related side effects, skin rashes, hypothyroidism and liver enzyme elevations. Preceding administration of glucocorticosteroids or other immunosuppressive drugs is expected to impair the efficacy of avelumab.

6.9.1.4 Bicalutamide

Bicalutamide is a non-steroidal antiandrogen (androgen receptor antagonist) that is approved for the antihormonal therapy of prostate cancer. No adverse effects have been reported from

adjuvant monotherapy for androgen receptor-positive salivary gland carcinomas [75]. Common side effects according to the prescribing information are skin rashes, weight loss, weight gain, anemia, loss of appetite, diabetic metabolic disorder, loss of libido, depression, abdominal complaints such as diarrhea or constipation, liver enzyme elevations, alopecia, skin dryness, sweating, itching, muscle and bone pain, thoracic tenderness and gynecomastia. Bicalutamide is mainly metabolized in the liver by oxidation and glucuronidation, but the enzymes involved are unknown. An involvement of CYP3A4 seems possible. Theoretically, the concomitant use of drugs that inhibit different CYP enzymes may therefore increase the plasma concentrations of bicalutamide, while inducers of CYP enzymes may decrease the plasma concentrations of bicalutamide. Bicalutamide is a weak inhibitor of CYP3A4 and led to an increase in the bioavailability of the CYP3A4 substrate midazolam by up to 80%. This increase may be significant for CYP3A4 substrates with a narrow therapeutic range (e.g., ciclosporin). In some cases, the risk of bleeding was increased or bleeding events occurred during concomitant treatment with vitamin K antagonists and bicalutamide. It is assumed that bicalutamide displaces the vitamin K antagonists from plasma protein binding. The risk of torsades de pointes due to the intake of QT time-prolonging drugs may be increased by the simultaneous administration of bicalutamide, as it can prolong the QT interval. Patients with risk factors for QT prolongation should be monitored electrocardiographically. When administering ciclosporin, careful monitoring of plasma concentrations during treatment with bicalutamide is recommended. Patients receiving concomitant treatment with vitamin K antagonists should also be closely monitored.

6.9.1.5 Cabozantinib

Cabozantinib is a multikinase inhibitor. In addition to the VEGFR1, VEGFR2 and VEGFR3 kinases, it also inhibits AXL and MET. Cabozantinib is approved for the treatment of renal cell carcinoma, hepatocellular carcinoma and differentiated thyroid carcinoma. A phase II trial in patients with salivary gland carcinoma was terminated prematurely due to excessive toxicity in the area of previously irradiated wounds [120]. The most common adverse events leading to dose reduction in larger clinical trials with cabozantinib were diarrhea (16%), palmpantar erythrodysesthesia (11%) and fatigue (10%).

Cabozantinib has very high plasma protein binding. As a result, it can displace other drugs that are strongly bound to plasma proteins from plasma protein binding. This can lead to an increase in the desired and undesired effects of drugs with a narrow therapeutic range if their degradation and excretion pathways are restricted at the same time. If cabozantinib is taken with a very high-fat meal, its oral bioavailability is increased by 57% compared to taking cabozantinib with an empty stomach. Cabozantinib is mainly metabolized via CYP3A4. Concomitant treatment with strong inducers of CYP3A4 may reduce the systemic availability of cabozantinib and thus its clinical efficacy. Concomitant treatment with strong inhibitors of CYP3A4 may result in increased adverse effects. Concomitant treatment with drugs that are strong CYP3A4 inducers or CYP3A4 inhibitors should be avoided. The consumption of grapefruit, grapefruit-like fruits (e.g., pomelo, bitter orange) and their preparations should be avoided for the entire duration of treatment with cabozantinib. Myelosuppression caused by cabozantinib, which occurs frequently, can be exacerbated by the simultaneous use of other myelosuppressive drugs. Since electrolyte dysbalances have been observed frequently during treatment with cabozantinib, concomitant treatment with cabozantinib and QT-prolonging drugs may increase the risk of the occurrence of polymorphic ventricular arrhythmias (torsade de pointes). During treatment with cabozantinib, peripheral blood counts should be monitored. Concomitant treatment with cabozantinib and QT time-prolonging drugs should be avoided. If this is not possible, attention should be paid to electrolyte balance and the QT time should be checked regularly. Cabozantinib may cause severe bleeding. This risk is increased by the simultaneous administration of cabozantinib with anticoagulant drugs. In the case of concomitant treatment with cabozantinib and anticoagulants, coagulation-related laboratory parameters should be checked

regularly. Cases of gastrointestinal perforation have been reported in clinical studies. This risk may be increased by concomitant use of cabozantinib with substances with a known risk of gastrointestinal perforation, so these drugs should be avoided.

6.9.1.6 Carboplatin

Carboplatin is a platinum derivative that has been used in combination with paclitaxel for palliative therapy in patients with salivary gland carcinoma [93]. Neutropenia, nausea, vomiting, alopecia, diarrhea or constipation have been reported as frequent side effects. Rarely, neurotoxicity may also occur.

6.9.1.7 Cetuximab

Cetuximab is a monoclonal antibody against the EGF receptor. It has been approved for the treatment of colorectal carcinomas and head and neck squamous cell carcinomas. Side effects (grade 3/4), which occurred in more than 5% of patients in the approval studies, were acneiform dermatitis and infusion reactions. Prophylactic treatment of acneiform dermatitis should be carried out with doxycycline or minocycline.

6.9.1.8 Cisplatin

Cisplatin is a platinum derivative that is used as palliative monotherapy [94], in addition to curative radiotherapy or as palliative combination therapy with docetaxel and cyclophosphamide (CAP protocol) for salivary gland carcinoma. It is approved for the treatment of testicular carcinoma, ovarian carcinoma, bladder cancer, squamous cell carcinoma of the head and neck, small cell and non-small cell lung carcinoma and cervical carcinoma. Major side effects reported include nausea and vomiting, nephrotoxicity, polyneuropathy, ototoxicity, hematotoxicity, electrolyte imbalances, cardiotoxicity and diarrhea. Vaccination with live vaccines (e.g., yellow fever) is contraindicated. The prescribing information points at relevant pharmacological interactions with other active substances such as ototoxic or nephrotoxic substances, anticoagulants, anticonvulsants or phenytoin as well as increased effect when combined with paclitaxel, docetaxel, bleomycin, vinorelbine or cyclosporine.

6.9.1.9 Cyclophosphamide

Cyclophosphamide is a widely used cytotoxic chemotherapeutic agent from the alkylant class of substances, which is frequently used in dose-intensive combination therapies and is associated with a very broad spectrum of possible side effects (see prescribing information). Myelotoxicity (grade II-III neutropenia) and grade II mucositis have been reported in palliative use at moderate doses in combination with doxorubicin and cisplatin for the treatment of salivary gland carcinoma (CAP protocol) [91]. Clinically relevant drug interactions with aprepitant, ciprofloxacin, azole antifungals, macrolide antibiotics, sulfonamides, prasugrel, thiotepa, ondansetron or allopurinol, for example, are described in the prescribing information. Potential cardiotoxicity must be taken into account in combination with anthracyclines.

6.9.1.10 Dabrafenib

Dabrafenib is a tyrosine kinase inhibitor directed against BRAF. It has been approved for the treatment of melanoma and non-small cell lung cancer. Clinical response has been described in BRAF-mutated salivary duct carcinoma in combination with the MEK inhibitor trametinib [106].

In monotherapy, cutaneous side effects including new squamous cell carcinomas, fatigue and fever reactions have been reported.

Both in monotherapy and in combination therapy with trametinib, dabrafenib should be taken at least one hour before a meal or as far away as possible from a previous meal. If dabrafenib is taken with food, its oral bioavailability is reduced by 31% compared to taking it with an empty stomach. Dabrafenib has a very high plasma protein binding, so that it can displace other drugs strongly bound to plasma proteins from plasma protein binding. This can lead to an increase in the desired and undesired effects of drugs with a narrow therapeutic range if their degradation and excretion pathways are restricted. Dabrafenib is degraded by CYP2C8 and CYP3A4. The resulting active metabolites hydroxydabrafenib and desmethyl-dabrafenib are also substrates of CYP3A4. Concomitant treatment with crizotinib and strong inducers of CYP3A4 or CYP2C8 may reduce the systemic availability of dabrafenib and its active metabolites and thus their clinical efficacy. Concomitant treatment with strong inhibitors of CYP3A4 or CYP2C8 may result in increased adverse effects. The concomitant administration of dabrafenib with drugs that are inducers or strong inhibitors of CYP3A4 or CYP2C8 should be avoided. The concomitant administration of dabrafenib with drugs that are substrates of CYP3A4 and have a narrow therapeutic range may therefore lead to a reduction or loss of clinical efficacy of these drugs. If concomitant treatment with dabrafenib and drugs that are CYP3A4 substrates with a narrow therapeutic range is necessary, patients must be closely monitored for adverse effects.

6.9.1.11 Docetaxel

Docetaxel is a taxane. In HER2-positive salivary gland carcinoma, it is used in combination with trastuzumab [99]; it is also used in palliative therapy in combination with carboplatin or as monotherapy. It is approved for the treatment of breast carcinoma, adenocarcinoma of the stomach, non-small cell lung carcinoma, prostate carcinoma and head and neck carcinoma. Severe grade 3 or 4 side effects include infections, nail changes, stomatitis and diarrhea, while grade 2 side effects include alopecia. Polyneuropathy, sometimes irreversible, is particularly troublesome. Common side effects such as nausea/vomiting and allergic reactions can be prevented by adequate supportive care, see [Onkopedia Antiemesis](#).

6.9.1.12 Doxorubicin

Doxorubicin (synonym: adriamycin) is a cytotoxic chemotherapeutic agent from the anthracycline class of substances. It is used in salivary gland carcinomas in combination with cyclophosphamide and cisplatin (CAP protocol) [90, 91]. It is approved for a wide range of malignant neoplasms (breast carcinoma, lung carcinoma, ovarian carcinoma, endometrial carcinoma, bladder carcinoma, sarcomas, Wilms' tumor, thyroid carcinoma, neuroblastoma, Hodgkin's and non-Hodgkin's lymphomas, acute leukemias, myeloma). In addition to cardiotoxicity (maximum cumulative total dose in adults 550 mg/m²), particular attention should be paid to hematotoxicity. Doxorubicin should be administered via a safe venous access due to its tissue-damaging effect.

6.9.1.13 Entrectinib

Entrectinib is a strong inhibitor of neurotrophic tropomyosin receptor kinases (NTRK) A, B, and C and is approved for the treatment of NTRK fusion-positive tumors and ROS1-mutated non-small cell lung cancer. From three tumor-agnostic studies [97], taste disturbances, constipation, diarrhea, fatigue, confusion, increased serum creatinine, paresthesia, nausea, vomiting, arthralgia, myalgia and weight gain as well as individual cases of severe neurotoxicity were reported as adverse effects.

6.9.1.14 Enzalutamide

Enzalutamide is a pure androgen receptor antagonist with approximately 10 times higher androgen receptor affinity than bicalutamide. It is approved for the antihormonal treatment of prostate cancer. The main side effects reported are fatigue, hypertension, hot flashes, weight loss, drowsiness, diarrhea and peripheral edema.

Enzalutamide is primarily metabolized via CYP2C8, resulting in an active metabolite. The simultaneous administration of inhibitors of CYP2C8 leads to an increase in the systemic availability of enzalutamide, which can increase undesirable effects. The simultaneous administration of inducers of CYP2C8 does not lead to a clinically relevant change in the systemic availability of enzalutamide. Increased formation of active metabolites is also possible (e.g., clopidogrel). The full induction potential of enzalutamide often only becomes apparent after one month, when the steady state of the clinical drug concentration of enzalutamide has been reached, but induction effects may also occur earlier. If the simultaneous administration of enzalutamide and drugs that are strong CYP2C8 inhibitors is necessary, the dose of enzalutamide should be reduced to 80 mg once daily (prescribing information as of May 2024). Enzalutamide is considered a strong inducer of CYP3A4 and a moderate inducer of CYP2C9 and CYP2C19. The concomitant use of enzalutamide with drugs that are substrates of CYP3A4, CYP2C19 or CYP2C9 can lead to significant reductions in systemic availability and to a sharp decrease or loss of clinical efficacy of the drugs. When taking drugs that are substrates of CYP3A4, CYP2C9 or CYP2C19 at the same time, patients should be monitored in the first month of treatment with enzalutamide for a loss of pharmacological effect or an increase in effect due to increased formation of active metabolites. A dose adjustment may need to be considered. Due to the long half-life of enzalutamide, it should be noted that the effect on the CYP enzymes may persist for a month or longer after the end of treatment. Enzalutamide therapy can lead to a prolongation of the QT interval. Concomitant treatment with enzalutamide and other QT time-prolonging drugs may increase the risk of polymorphic ventricular arrhythmias (torsade de pointes). The simultaneous treatment of enzalutamide with drugs that prolong the QT time should be avoided. If this is not possible, care should be taken to maintain a balanced electrolyte balance and the QT time should be checked regularly. The risk of seizures during treatment with enzalutamide is increased in patients taking drugs that lower the seizure threshold.

6.9.1.15 Epirubicin

Epirubicin is a cytotoxic chemotherapeutic agent from the anthracycline class of substances, which is approved for the treatment of breast cancer, ovarian cancer, gastric cancer and small cell lung cancer. The most important side effects are myelosuppression and cumulative cardiotoxicity (maximum total dose 900 mg/m² epirubicin hydrochloride according to the prescribing information). In a study on the palliative treatment of salivary gland carcinoma [95], alopecia, nausea, vomiting, mucositis and a tissue reaction at the peripheral venous access were reported as adverse effects.

6.9.1.16 Goserelin

Goserelin is a GnRH analog approved for the antiandrogenic therapy of prostate cancer. It is applied subcutaneously under the abdominal skin every 3 months. No adverse effects have been reported from palliative monotherapy for androgen receptor-positive salivary gland carcinomas [75]. According to the prescribing information, the most common side effects are impaired glucose tolerance, loss of libido, heart failure, hot flashes, sweating, skin rashes, bone pain, erectile dysfunction and local reactions at the injection site.

6.9.1.17 Larotrectinib

Larotrectinib is a selective NTRK inhibitor that is approved for the treatment of NTRK fusion-positive tumors. From a study on its use in salivary gland carcinomas [96], liver enzyme elevations, confusion, constipation, fatigue, muscle and joint pain, nausea, peripheral edema, headache, weight gain, hyperglycemia and peripheral neuropathy were reported as side effects. The prescribing information states that if concomitant administration with a strong CYP3A4 inhibitor is necessary, the larotrectinib dose should be reduced by 50 %. After discontinuation of the inhibitor for 3 to 5 elimination half-lives, treatment should be continued at the dose taken prior to treatment with the CYP3A4 inhibitor.

6.9.1.18 Lenvatinib

Lenvatinib is a multi-tyrosine kinase inhibitor that inhibits VEGFR1-3, FGFR1-4, PDGFR α , PDGF, KIT and RET. In a study on palliative use in adenoid cystic salivary gland carcinoma [107], the main side effects reported were hypertension and pain in the mouth; 18 of 32 patients discontinued treatment due to drug-associated side effects. According to the prescribing information, proteinuria, hepatotoxicity, aneurysms, aortic dissections, renal failure, diarrhea, CNS toxicity, fistulas/perforations, bleeding, arterial thromboembolism, wound healing disorders, osteonecrosis of the jaw, thyroid dysfunction and cardiac dysfunction such as QT prolongation may also occur.

Myelosuppression caused by lenvatinib can be exacerbated by the concomitant use of other myelosuppressive drugs. Since prolongation of ventricular repolarization has been observed during therapy with lenvatinib, concomitant administration of lenvatinib with QT time-prolonging drugs may increase the risk of polymorphic ventricular arrhythmias (torsade de pointes). Concomitant treatment with lenvatinib and QT-prolonging drugs should be avoided. If this is not possible, attention should be paid to a balanced electrolyte balance and the QT time should be checked regularly. Bleeding may also occur with the use of lenvatinib. Concomitant treatment with lenvatinib and anticoagulant drugs can further increase the risk of bleeding. Co-treatment with lenvatinib and anticoagulants should be accompanied by regular monitoring of coagulation-related laboratory parameters. Renal dysfunction, especially acute renal insufficiency, frequently occurs during treatment with lenvatinib. Concomitant administration of lenvatinib and drugs that interfere with the renin-angiotensin-aldosterone system (RAAS) may result in an increased risk of acute renal failure. If lenvatinib and drugs that interfere with the RAAS are administered at the same time, renal function should be monitored regularly. Gastrointestinal perforations have been observed during treatment with lenvatinib. The risk of this may be increased by the simultaneous administration of lenvatinib and drugs that interfere with prostaglandin metabolism (e.g., NSAIDs, corticosteroids). The administration of corticosteroids or NSAIDs during therapy with lenvatinib should be avoided. Lenvatinib is mainly degraded via oxidation by aldehyde oxidase. N-demethylation via CYP3A4 and glutathione conjugation are secondary pathways of degradation. Therefore, both CYP3A4 inhibitors and CYP3A4 inducers have no significant influence on the systemic availability of lenvatinib.

6.9.1.19 Leuprorelin

Leuprorelin is a GnRH analog approved for the antiandrogenic therapy of prostate cancer. It is administered subcutaneously every 6 months. No adverse effects have been reported from monotherapy for androgen receptor-positive salivary gland carcinomas [75]. According to the prescribing information, the most common side effects are skin rashes, nasopharyngitis, hot flashes, nausea, diarrhea, enteritis, itching, night sweats, bone/joint/muscle pain, urinary reten-

tion, dysuria, anemia, prolonged clotting time, thoracic tenderness, gynecomastia, erectile dysfunction, loss of libido and local reactions at the injection site.

Leuprorelin can lead to a prolongation of the QT interval. In patients with a history of QT prolongation or risk factors for QT prolongation and in patients taking concomitant drugs that may prolong the QT interval, physicians should consider the risk-benefit ratio, including the potential for torsade de pointes tachycardia, before initiating treatment with leuprorelin. Regular monitoring of ECG and electrolytes should be considered.

6.9.1.20 Nivolumab

Nivolumab is a humanized anti-PD1 monoclonal antibody and belongs to the class of immune checkpoint inhibitors. It has been approved as a monotherapy and combination therapy for the treatment of a broad spectrum of malignant neoplasms including head and neck squamous cell carcinoma. In a study on palliative nivolumab monotherapy of salivary gland carcinomas [88], anemia, hypoalbuminemia, hyperkalemia, liver enzyme elevations, heart failure, serum amylase elevation, hyponatremia, creatine phosphokinase elevation and renal dysfunction were reported. Other possible side effects include skin rash, diarrhea and loss of appetite, as well as sometimes severe pyrexia and interstitial pneumonia (immune-mediated pneumonitis), immune-mediated liver or kidney inflammation and endocrinopathies. Preceding administration of immunosuppressive drugs is expected to impair the efficacy of nivolumab.

6.9.1.21 Paclitaxel

Like docetaxel, paclitaxel is a cytotoxic chemotherapeutic agent from the taxane class. It is approved for the treatment of breast carcinoma, ovarian carcinoma, non-small cell lung carcinoma and AIDS-associated Kaposi's sarcoma. As it has not shown efficacy as a monotherapeutic agent in salivary gland carcinomas, it is generally used in combination with carboplatin or cetuximab [92, 93]. Severe side effects can include infections, stomatitis and diarrhea as well as allergic reactions to the solvent cremophor. Premedication with glucocorticoids, H2 receptor antagonists and antihistamines is mandatory. Alopecia is one of the most troublesome side effects, and polyneuropathy, which can be irreversible, is particularly burdensome.

The metabolism of paclitaxel is catalyzed in part by the cytochrome P450 isoenzymes CYP2C8 and CYP3A4. Therefore, special caution is required when paclitaxel is used together with other drugs that inhibit CYP2C8 or CYP3A4 (e.g., azole antifungals, erythromycin, fluoxetine, gemfibrozil, clopidogrel, cimetidine, ritonavir, saquinavir, indinavir or nelfinavir), as the toxicity of paclitaxel may be increased due to higher paclitaxel exposure. The use of paclitaxel together with drugs that induce CYP2C8 or CYP3A4 (e.g., rifampicin, carbamazepine, phenytoin, efavirenz, nevirapine) is not recommended as efficacy may be impaired due to lower paclitaxel exposure.

6.9.1.22 Pembrolizumab

Pembrolizumab is an immune checkpoint inhibitor. It is a fully human monoclonal antibody of the immunoglobulin G4 (IgG4) class that binds to the PD-1 receptor on T cells and prevents interaction with the PD1 receptor ligand that actually binds here. It is approved for the treatment of a broad spectrum of malignant neoplasms including head and neck squamous cell carcinoma. In patients with salivary gland carcinomas, it has been used in studies as monotherapy or in combination with radiotherapy. Relevant pharmacological interactions have not been described. Preceding administration of immunosuppressive drugs is expected to impair the efficacy of pembrolizumab. As with other immune checkpoint inhibitors, there is a risk of

immune-mediated, sometimes severe, side effects such as pneumonitis, endocrinopathy, nephritis, hepatitis, colitis or skin reactions.

6.9.1.23 Pertuzumab

Pertuzumab is a humanized antibody directed against HER2 approved for use in combination with trastuzumab and docetaxel in HER2-positive breast cancer. As part of a "basket" study, it was used in combination with trastuzumab in patients with salivary gland carcinoma [102]. According to the prescribing information, the order of administration is arbitrary. In addition to an infusion reaction, left ventricular dysfunction may occur as a side effect when pertuzumab is given in combination with trastuzumab. Regular monitoring of left ventricular heart function by echocardiography should be performed during ongoing therapy. Another serious side effect can be diarrhea, which can be severe in some cases. Relevant pharmacological interactions have not been described.

6.9.1.24 Pralsetinib

Pralsetinib is a potent selective inhibitor of RET receptor tyrosine kinase that is approved for the treatment of RET fusion-positive non-small cell lung cancer. In a tumor-agnostic phase I/phase II study, liver enzyme elevations, neutropenia, anemia, thrombocytopenia, constipation and weight loss were reported as adverse events. The prescribing information mentions respiratory tract infections, urinary tract infections, hyperphosphatemia, hypophosphatemia, hypocalcemia, hyponatremia, hypoalbuminemia, headache, taste disturbances, hypertension, bleeding tendency, diarrhea, gastrointestinal complaints such as nausea and vomiting, dry mouth, skin rash, mucositis, musculoskeletal pain, fatigue, edema, fever, QT prolongation and serum creatinine elevation as possible further side effects. With simultaneous administration of P-glycoprotein inhibitors (cyclosporine, quinidine, carvedilol, diltiazem, dronedarone, verapamil, erythromycin, etc.) and/or CYP3A4 inhibitors (azole antifungals, macrolide antibiotics, nelfinavir, saquinavir, ritonavir, aprepitant, idelalisib, imatinib, grapefruit juice), the dosage of pralsetinib must be reduced (see prescribing information). The simultaneous administration of moderate or strong CYP3A4 inducers (carbamazepine, St. John's wort, rifabutin, rifampicin, phenytoin, etc.) should be avoided.

6.9.1.25 Selpercatinib

Selpercatinib is a highly selective RET kinase inhibitor. It is approved across tumor entities for the treatment of RET fusion-positive tumors and RET-mutated thyroid carcinomas. The main side effects in the cross-entity phase I/phase II study [104] were hypertension and liver enzyme elevation, as well as fatigue, proteinuria and abdominal discomfort. Severe treatment-related adverse events were reported in 40% of patients. The prescribing information also lists pneumonia, hypersensitivity reactions, headache, QT prolongation, bleeding, interstitial pneumonitis, gastrointestinal complaints such as nausea, vomiting, diarrhea or constipation, edema and myelosuppression as frequent side effects.

In patients with known QT prolongation, special cardiological examinations are recommended prior to the use of selpercatinib (see prescribing information). Due to its metabolization via CYP3A4 and P-glycoprotein and its influence on CYP2C8, selpercatinib has numerous interactions with other drugs and active substances (St. John's wort) and its absorption after oral administration is influenced by proton pump inhibitors (PPI). Please refer to the detailed information in the prescribing information.

6.9.1.26 Sorafenib

Sorafenib is a multi-kinase inhibitor that inhibits the Raf and VEGF signaling pathways as well as PGFR-alpha and -beta, KIT and RET. It has been approved for the treatment of renal cell carcinoma, hepatocellular carcinoma and differentiated thyroid carcinoma. In palliative monotherapy of patients with salivary gland carcinoma [108], side effects \geq grade 3 were reported in almost 30%, predominantly skin rashes, hand-foot syndrome, mucositis, lung infections, fatigue, arterial thrombosis and gastrointestinal complaints. Sorafenib has been extensively studied for its pharmacological interaction potential (see prescribing information). Of particular clinical relevance is the interaction with CYP3A4 inducers such as St. John's wort, phenytoin, dexamethasone or carbamazepine, which can lead to a reduction in sorafenib bioavailability.

6.9.1.27 Trametinib

Trametinib is an orally administered MEK inhibitor that is approved in combination with the BRAF inhibitor dabrafenib for the treatment of BRAF-V600-mutated melanomas. This combination has also been used sporadically in patients with BRAF V600-mutated salivary duct carcinomas [106]. Trametinib monotherapy is not effective in the aforementioned tumor entities. The prescribing information refers to possible side effects such as QT prolongation, reduction in left ventricular ejection fraction, high blood pressure, febrile states or visual disturbances and mentions interstitial pneumonitis as a particular possible complication. Trametinib is deacetylated by hydrolytic enzymes such as carboxylesterase. Due to this metabolization, an interaction via other metabolizing enzymes (e.g., CYP enzymes) is classified as rather unlikely. Bleeding may occur when trametinib is used. Concomitant treatment with trametinib and anticoagulants may further increase the risk of bleeding. Co-treatment with trametinib and anticoagulants should be accompanied by regular monitoring of coagulation-related laboratory parameters. If trametinib is taken with a high-fat, high-calorie meal, the maximum plasma concentration decreases by 70% compared to taking it on an empty stomach, and oral bioavailability is reduced by 10%. Trametinib should be taken on an empty stomach, i.e., at least one hour before a meal or as far away as possible from a previous meal.

6.9.1.28 Trastuzumab

Trastuzumab is a humanized monoclonal antibody that binds to the epidermal growth factor receptor HER2 on the cell surface and thereby inhibits cell growth. It has been approved for the treatment of HER2-positive breast cancer and gastric cancer. In a study on palliative therapy in combination with docetaxel in the treatment of HER2-positive salivary duct carcinoma [99], the most common side effects described were myelosuppression, febrile neutropenia, hypoalbuminemia, edema, liver enzyme elevations, weight loss, fatigue, constipation and electrolyte dysbalances. The prescribing information also lists skin rashes, respiratory tract infections, hypersensitivity reactions, muscle and joint pain, impaired renal function, conjunctivitis, hot flashes and respiratory complaints as frequent side effects. Particular attention should be paid to cardiac dysfunction such as left heart failure and arrhythmias.

Clinically significant pharmacological interactions with other drugs and active substances were not registered in studies.

6.9.1.29 Trastuzumab emtansine

Trastuzumab emtansine (T-DM1) is an antibody-drug conjugate directed against HER2, coupled with an antimicrotubular substance. It is approved for the treatment of HER2-positive breast cancer. In the treatment of HER2-positive malignancies [100] in the NCI-MATCH study, a rele-

vant clinical response was observed in HER2-positive salivary gland carcinomas. The most common side effects reported were anemia, thrombocytopenia, fatigue, nausea/vomiting, liver enzyme elevations and weight loss. The prescribing information also lists urinary tract infections, headaches, polyneuropathy, sleep disorders, gastrointestinal complaints, muscle and joint pain and a tendency to bleed. Interstitial pneumonitis is described as a rare, sometimes severe side effect.

Trastuzumab emtansine is mainly metabolized via CYP3A4, to a lesser extent also via CYP3A5. Active substances that inhibit CYP3A4, e.g., azole antifungals, clarithromycin, telithromycin, numerous antiviral substances, especially for HIV treatment, should not be administered at the same time as trastuzumab emtansine if possible.

6.9.1.30 Trastuzumab deruxtecan (T-DXd)

Trastuzumab deruxtecan is an antibody-drug conjugate directed against HER2; the coupled drug is a topoisomerase inhibitor. In the tumor-agnostic phase II trial for use in HER2-positive malignancies [103], a response rate of 42% was reported among 19 included patients with salivary gland carcinoma. The approval currently covers the treatment of HER2-positive breast carcinoma, lung carcinoma and gastric carcinoma (as of January 2024). In the USA, there is a tumor-agnostic approval for the treatment of HER2-positive tumors.

When using a dosage of 5.4 mg/kg every 3 weeks, grade 3-4 side effects were observed in 40% of patients, mainly nausea/vomiting, anemia, diarrhea, fatigue, inappetence, weight loss and alopecia. A particular side effect is interstitial pneumonitis, which is sometimes life-threatening and has been documented in 10-30% of patients treated in studies with patients with various underlying malignancies. However, in some of these studies T-DXd was also administered at a higher dose (6.4 mg/kg every 3 weeks).

Clinically relevant pharmacological interactions with other active substances have not yet been found in studies. The prescribing information also contains no indications of such interactions.

6.9.1.31 Triptorelin

Triptorelin is a GnRH analog approved for the antiandrogenic therapy of prostate cancer. Outside of malignant diseases, it is approved for hormone therapy in adults with endometriosis or uterine myomatosis. It is injected subcutaneously or deep intramuscularly every 4 weeks. Adverse effects were not specified from a study on combination therapy with bicalutamide in androgen receptor-positive salivary gland carcinomas [113]. According to the prescribing information, the most common side effects are hypersensitivity, loss of libido, depression, sleep disturbance, hot flashes, nausea, sweating, bone/joint/muscle pain, erectile dysfunction, gynecomastia or local reactions at the injection site.

Due to potential QT prolongation, concomitant administration with substances such as quinine, disopyramide, amiodarone, sotalol, methadone, moxifloxacin or neuroleptics must be carefully evaluated according to the prescribing information.

6.9.1.32 Vinorelbine

Vinorelbine is a cytotoxic chemotherapeutic agent from the vinca alkaloid class of substances, which blocks mitosis by inhibiting the formation of microtubules and nuclear spindles. It is approved for the treatment of lung and breast carcinomas. In a phase II trial for palliative use in salivary gland carcinomas [90], myelosuppression, nausea/vomiting, peripheral neurotoxicity and alopecia were reported as adverse effects. According to the prescribing information, the

most common side effects are bone marrow depression with neutropenia, anemia and thrombocytopenia, gastrointestinal toxicity with nausea, vomiting, diarrhea, mucositis and constipation as well as fatigue and fever. The contraindication of vaccination with live vaccines during treatment with vinorelbine must be emphasized. In addition, there are complex, and in some cases life-threatening, interactions with other active substances such as triazole antifungals, macrolide antibiotics, St. John's wort, HIV-targeted protease inhibitors, rifampicin, carbamazepine, phenytoin, etc., so that particularly careful consideration of the prescribing information is required before starting treatment with vinorelbine.

7 Rehabilitation

Rehabilitation follows the same principles as for common head and neck tumors (see [Onkopedia guideline on head and neck cancer](#)): Salivary gland carcinomas or their treatment with surgery, radiotherapy or systemic drug therapy often result in considerable distress, loss of quality of life as well as functional and somatic sequelae. As a result of these side effects and the oncological diagnosis itself, there is a high psychological burden and a corresponding need for psycho-oncological and psychosocial care. Targeted rehabilitation measures are therefore indicated. They should start as soon as possible after completion of the primary therapy. General therapeutic measures (sports/physio-/occupational therapy) should be offered during rehabilitation. The costs of dental rehabilitation with dental implants following treatment for salivary gland carcinoma are usually covered by health insurances (§28 SGB V). Rehabilitation facilities should be able to continue drug-based tumor therapies if indicated. Patients who have not yet reached the statutory retirement age should be informed about benefits for participation in working life as part of medical-occupational rehabilitation (MBOR). Further socio-medical questions and necessary care for the patient should be clarified during rehabilitation. Furthermore, all patients should be offered psycho-oncological care. Patients should also be recommended to the self-help groups for head and neck tumors.

8 Follow-up and monitoring

Structured follow-up is recommended for patients after curative treatment of salivary gland carcinoma. The clinical follow-up examinations take place every 3 months in the 1st and 2nd year after initial treatment. This is followed by a monitoring every 6 months in the 3rd to 5th year. An US check of the tumor region and the soft tissues of the neck is carried out every 6 months in the 5 years after initial treatment. In the case of advanced tumors, US checks are recommended every 3 months in the first two years. An MRI neck with contrast medium (or a CT with CM if no MRI is possible) is carried out every 12 months in the first two years and over 5 years if there is a higher-risk constellation. In the case of a higher-risk constellation, a CT thorax should also be performed every 12 months for 5 years and, in the case of adenoid cystic carcinoma, a low-dose CT in the 6th to 10th year.

PET-CT is reserved for special questions and for patients after curative radiochemotherapy in order to do a neck dissection of positive lymph nodes. In addition, sectional imaging should be performed in the case of clinical complaints or suspicious clinical examination findings.

Follow-up should be continued over a period of ten years and, in the case of adenoid cystic carcinoma, for life.

9 References

1. Oesterling F, Kajuter H, Nachtsheim L, Loning T, Stang A. Letter: Parotid gland metastases of cutaneous squamous cell carcinoma - a corroboration at population level. *Head Neck Pathol* 2022;16:836-837. DOI:10.1007/s12105-022-01443-8

2. Ihrler S, Guntinas-Lichius O, Haas C, Mollenhauer M. WHO-Klassifikation 2017: Neues zu Tumoren der Speicheldrüsen. *Der Pathologe*. 2018;39(11):1-17. DOI:10.1007/s00292-017-0407-5
3. Mueller SK, Haderlein M, Lettmaier S et al. Targeted therapy, chemotherapy, immunotherapy and novel treatment options for different subtypes of salivary gland cancer. *J Clin Med* 2022;11:720. DOI:10.3390/jcm11030720
4. Cancer Incidence in Five Continents (CI5) Volume XII. <https://ci5.iarc.fr/ci5-xii> (2023). Accessed 19-JAN-2024.
5. Guntinas-Lichius O, Wendt TG, Buentzel J et al. Incidence, treatment, and outcome of parotid carcinoma, 1996-2011: a population-based study in Thuringia, Germany. *J Cancer Res Clin Oncol* 2015;141:1679-1688. DOI:10.1007/s00432-015-1961-y
6. Nachtsheim L, Mayer M, Meyer MF et al. Incidence and clinical outcome of primary carcinomas of the major salivary glands: 10-year data from a population-based state cancer registry in Germany. *J Cancer Res Clin Oncol* 2023;149:3811-3821. DOI:10.1007/s00432-022-04278-6
7. Steuer CE, Hanna GJ, Viswanathan K et al. The evolving landscape of salivary gland tumors. *CA Cancer J Clin* 2023;73:597-619. DOI:10.3322/caac.21807
8. Ord RA, Carlson ER. Pediatric salivary gland malignancies. *Oral Maxillofac Surg Clin North Am* 2016;28:83-89. DOI:10.1016/j.coms.2015.07.007
9. Coleman M, Liang J, Rastatter JC et al. Exploring the epidemiology and survival trends in pediatric major salivary gland malignancies: insights from the National Cancer Database. *Curr Oncol* 2023;30:6134-6147. DOI:10.3390/currenol30070456
10. International Agency for Research on Cancer. Global Cancer Observatory. Cancer Tomorrow: Salivary glands, Germany, 2024. https://gco.iarc.fr/tomorrow/en/dataviz/isotype?cancers=2&single_unit=50&populations=276. Accessed 29-APRIL-2024.
11. Keim U, Katalinic A, Holleczeck B, Wakkee M, Garbe C, Leiter U. Incidence, mortality and trends of cutaneous squamous cell carcinoma in Germany, the Netherlands, and Scotland. *Eur J Cancer* 2023;183:60-68. DOI:10.1016/j.ejca.2023.01.017
12. Krebs in Deutschland für 2019/2020. 14. Ausgabe ed. Berlin: Robert Koch-Institut und die Gesellschaft der epidemiologischen Krebsregister in Deutschland e.V.; 2023. <https://www.krebsdaten.de/Krebs/DE/Content/Publikationen/>
13. Moretz-Sohn PF, Dias FL, de Carvalho Marques CM. Minor salivary gland cancer of the head and neck: a review of epidemiologic aspects, prognostic factors, and outcomes. *Curr Oncol Rep* 2023;25:173-179. DOI:10.1007/s11912-022-01356-3
14. Iyer J, Hariharan A, Cao UMN et al. An overview on the histogenesis and morphogenesis of salivary gland neoplasms and evolving diagnostic approaches. *Cancers* 2021;13:3910. DOI:10.3390/cancers13153910
15. Mat Lazim N, Yousaf A, Abusalah MAH et al. The epigenesis of salivary glands carcinoma: from field cancerization to carcinogenesis. *Cancers* 2023;15:2111. DOI:10.3390/cancers15072111
16. Horn-Ross PL, Ljung BM, Morrow M. Environmental factors and the risk of salivary gland cancer. *Epidemiology* 1997;8:414-419. DOI:10.1097/00001648-199707000-00011
17. Swanson GM, Burns PB. Cancers of the salivary gland: workplace risks among women and men. *Ann Epidemiol* 1997;7:369-374. DOI:10.1016/s1047-2797(97)00041-0
18. Radoï L, Barul C, Menvielle G et al. Risk factors for salivary gland cancers in France: Results from a case-control study, the ICARE study. *Oral Oncol* 2018;80:56-63. DOI:10.1016/j.oraloncology.2018.03.019

19. Shebl FM, Bhatia K, Engels EA. Salivary gland and nasopharyngeal cancers in individuals with acquired immunodeficiency syndrome in United States. *Int J Cancer* 2010;126:2503-2508. [DOI:10.1002/ijc.24930](https://doi.org/10.1002/ijc.24930)
20. Thompson LDR, Whaley RD. Lymphoepithelial carcinoma of salivary glands. *Surg Pathol Clin* 2021;14:75-96. [DOI:10.1016/j.path.2020.09.009](https://doi.org/10.1016/j.path.2020.09.009)
21. Beck-Broichsitter B, Heiland M, Guntinas-Lichius O. Speicheldrüsentumoren: Limitationen der internationalen Guidelines und Bearbeitungsstand der AWMF-S3-Leitlinie. *Laryngo-Rhino-Otologie*. 2024;in press.
22. Thompson C, Nolli T, Bannister M. Parotid incidentalomas: a systematic review. *J Laryngol Otol* 2021;135:765-769. [DOI:10.1017/S0022215121002036](https://doi.org/10.1017/S0022215121002036)
23. Extermann M, Aapro M, Bernabei R et al. Use of comprehensive geriatric assessment in older cancer patients: recommendations from the task force on CGA of the International Society of Geriatric Oncology (SIOG). *Crit Rev Oncology Hematol* 2005;55:241-252. [DOI:10.1016/j.critrevonc.2005.06.003](https://doi.org/10.1016/j.critrevonc.2005.06.003)
24. Guntinas-Lichius O, Volk GF, Olsen KD et al. Facial nerve electrodiagnostics for patients with facial palsy: a clinical practice guideline. *Eur Arch Otorhinolaryngol* 2020;277:1855-1874. [DOI:10.1007/s00405-020-05949-1](https://doi.org/10.1007/s00405-020-05949-1)
25. Edafe O, Hughes B, Tsirevelou P, Goswamy J, Kumar R. Understanding primary parotid squamous cell carcinoma - a systematic review. *Surgeon* 2020;18:44-48. [DOI:10.1016/j.surge.2019.03.006](https://doi.org/10.1016/j.surge.2019.03.006)
26. Thielker J, Grosheva M, Ihrler S, Wittig A, Guntinas-Lichius O. Contemporary management of benign and malignant parotid tumors. *Front Surg* 2018;5:39. [DOI:10.3389/fsurg.2018.00039](https://doi.org/10.3389/fsurg.2018.00039)
27. Ali S, Bryant R, Palmer FL et al. Distant metastases in patients with carcinoma of the major salivary glands. *Ann Surg Oncol* 2015;22:4014-4019. [DOI:10.1245/s10434-015-4454-y](https://doi.org/10.1245/s10434-015-4454-y)
28. Sharma P, Jain TK, Singh H et al. Utility of (18)F-FDG PET-CT in staging and restaging of patients with malignant salivary gland tumours: a single-institutional experience. *Nucl Med Commun* 2013;34:211-219. [DOI:10.1097/MNM.0b013e32835bc4c4](https://doi.org/10.1097/MNM.0b013e32835bc4c4)
29. Rossi ED, Faquin WC, Baloch Z et al. The Milan system for reporting salivary gland cytopathology: Analysis and suggestions of initial survey. *Cancer* 2017;125:757-766. [DOI:10.1002/cncy.21898](https://doi.org/10.1002/cncy.21898)
30. Farahani SJ, Baloch Z. Retrospective assessment of the effectiveness of the Milan system for reporting salivary gland cytology: A systematic review and meta-analysis of published literature. *Diagn Cytopathol* 2019;47:67-87. [DOI:10.1002/dc.24097](https://doi.org/10.1002/dc.24097)
31. Kim HJ, Kim JS. Ultrasound-guided core needle biopsy in salivary glands: A meta-analysis. *Laryngoscope* 2018;128:118-125. [DOI:10.1002/lary.26764](https://doi.org/10.1002/lary.26764)
32. Douville NJ, Bradford CR. Comparison of ultrasound-guided core biopsy versus fine-needle aspiration biopsy in the evaluation of salivary gland lesions. *Head Neck* 2013;35:1657-1661. [DOI:10.1002/hed.23193](https://doi.org/10.1002/hed.23193)
33. Cho J, Kim J, Lee JS, Chee CG, Kim Y, Choi SI. Comparison of core needle biopsy and fine-needle aspiration in diagnosis of malignant salivary gland neoplasm: Systematic review and meta-analysis. *Head Neck* 2020;42:3041-350. [DOI:10.1002/hed.26377](https://doi.org/10.1002/hed.26377)
34. Ihrler S, Agaimy A, Guntinas-Lichius O et al. Why is the histomorphological diagnosis of tumours of minor salivary glands much more difficult? *Histopathology* 2021;79:779-790. [DOI:10.1111/his.14421](https://doi.org/10.1111/his.14421)

35. Guntinas-Lichius O, Thielker J, Robbins KT et al. Prognostic role of intraparotid lymph node metastasis in primary parotid cancer: systematic review. *Head Neck* 2021;43:997-1008. DOI:10.1002/hed.26541
36. Wittekind C. TNM Klassifikation maligner Tumoren. Korrigierter Nachdruck 2020 mit allen Ergänzungen der UICC aus den Jahren 2017 bis 2019. 8. Auflage ed. Weinheim: Wiley-VCH; 2020. ISBN: 978-3-527-34772-8
37. WHO Classification of Tumours Editorial Board. Head and neck tumours. Lyon (France): International Agency for Research on Cancer; 2022. (WHO classification of tumours series, 5th ed.; vol. 9). <https://publications.iarc.fr/>
38. Ihrler S, Jurmeister P, Haas C, Greber L, Agaimy A. Neues zu Tumoren der Speicheldrüsen. WHO-Klassifikation 2022. *Pathologie (Heidelb)* 2023;44:214-223. DOI:10.1007/s00292-023-01194-5
39. Ihrler S, Agaimy A, Guntinas-Lichius O, Haas C, Greber L. Warum ist die histomorphologische Diagnostik von Tumoren kleiner Speicheldrüsen so viel schwieriger? *Pathologie (Heidelb)* 2023;44:224-232. DOI:10.1007/s00292-023-01196-3
40. Rupp NJ, Freiburger SN. Speicheldrüsenkarzinome – ein aktueller Überblick. Fortschritte in der molekularen Typisierung: Teil I. *Pathologie (Heidelb)* 2022;43:467-474. DOI:10.1007/s00292-022-01123-y
41. Rupp NJ, Freiburger SN. Speicheldrüsenkarzinome – ein aktueller Überblick. Fortschritte in der molekularen Typisierung Teil II. *Pathologie (Heidelb)* 2023;44:70-77. DOI:10.1007/s00292-022-01171-4
42. Scherl C, Kramer B, Rotter N. Chirurgisches Vorgehen bei Speicheldrüsenkarzinomen. *Laryngorhinootologie* 2021;100:569-581. DOI:10.1055/a-1398-3652
43. Quer M, Guntinas-Lichius O, Marchal F et al. Classification of parotidectomies: a proposal of the European Salivary Gland Society. *Eur Arch Otorhinolaryngol* 2016;273:3307-3312. DOI:10.1007/s00405-016-3916-6
44. Mantsopoulos K, Iro H. Chirurgie der primären Karzinome der Gl. parotidea – Kontroverses und Bewährtes. *HNO* 2023;71:215-222. DOI:10.1007/s00106-022-01182-w
45. Guntinas-Lichius O, Klussmann JP, Schroeder U, Quante G, Jungehülsing M, Stennert E. Primary parotid malignoma surgery in patients with normal preoperative facial nerve function: outcome and long-term postoperative facial nerve function. *Laryngoscope* 2004;114:949-956. DOI:10.1097/00005537-200405000-00032
46. Thielker J, Kouka M, Guntinas-Lichius O. Erhalt, Rekonstruktion und Rehabilitation des N. facialis. *HNO* 2023;71:232-242. DOI:10.1007/s00106-022-01148-y
47. Guntinas-Lichius O, Silver CE, Thielker J et al. Management of the facial nerve in parotid cancer: preservation or resection and reconstruction. *Eur Arch Otorhinolaryngol* 2018;275:2615-2626. DOI:10.1007/s00405-018-5154-6
48. Klussmann JP, Ponert T, Mueller RP, Dienes HP, Guntinas-Lichius O. Patterns of lymph node spread and its influence on outcome in resectable parotid cancer. *Eur J Surg Oncol* 2008;34:932-937. DOI:10.1016/j.ejso.2008.02.004
49. Kejner AE, Harris BN. Extent and indications for elective and therapeutic neck dissection for salivary carcinoma. *Otolaryngol Clin North Am* 2021;54:641-651. DOI:10.1016/j.otc.2021.02.006
50. Yan F, Lao WP, Nguyen SA, Sharma AK, Day TA. Elective neck dissection in salivary gland malignancies: Systematic review and meta-analysis. *Head Neck* 2022;44:505-517. DOI:10.1002/hed.26923

51. Gu H, Zhou Y, Xuan G, Wang Y, Chen M. Elective neck dissection improves regional control in cN0 minor salivary gland carcinoma in the oral cavity. *J Oral Maxillofac Surg* 2023;81:504-510. DOI:10.1016/j.joms.2022.12.012
52. Mahmood U, Koshy M, Golubeva O, Suntharalingam M. Adjuvant radiation therapy for high-grade and/or locally advanced major salivary gland tumors. *Arch Otolaryngol Head Neck Surg*. 2011;137:1025-30. DOI:10.1001/archoto.2011.158
53. Terhaard CH. Postoperative and primary radiotherapy for salivary gland carcinomas: indications, techniques, and results. *Int J Radiat Oncol Biol Phys* 2007;69(2 Suppl):S52-55. DOI:10.1016/j.ijrobp.2007.04.079
54. Al-Qurayshi Z, Sullivan CB, Allison DB, Buchakjian MR. Presentation and outcomes of patients with clinically T1-2, N0 parotid mucoepidermoid carcinoma: The roles of elective neck dissection and adjuvant radiotherapy. *Head Neck* 2022;44:2151-2161. DOI:10.1002/hed.27128
55. Scarpa A, Viola P, Ralli M et al. Post-operative radiotherapy in adenoid cystic carcinoma of salivary glands versus surgery alone: what is the evidence about survival and local control? A systematic review and meta-analysis. *Eur Arch Otorhinolaryngol* 2024;281:563-571. DOI:10.1007/s00405-023-08252-x
56. North L, Stadler M, Massey B et al. Intermediate-grade carcinoma of the parotid and the impact of adjuvant radiation. *Am J Otolaryngol* 2019;40:102282. DOI:10.1016/j.amjoto.2019.102282
57. Zenga J, Yu Z, Parikh A et al. Mucoepidermoid carcinoma of the parotid: very close margins and adjuvant radiotherapy. *ORL J Otorhinolaryngol Relat Spec* 2019;81:55-62. DOI:10.1159/000497438
58. Zenga J, Parikh AS, Emerick KS, Lin DT, Faquin WC, Deschler DG. Close margins and adjuvant radiotherapy in acinic cell carcinoma of the parotid gland. *JAMA Otolaryngol Head Neck Surg* 2018;144:1011-1016. DOI:10.1001/jamaoto.2018.0788
59. Chen AM, Garcia J, Granchi P, Bucci MK, Lee NY. Base of skull recurrences after treatment of salivary gland cancer with perineural invasion reduced by postoperative radiotherapy. *Clin Otolaryngol* 2009;34:539-545. DOI:10.1111/j.1749-4486.2009.02036.x
60. Armstrong K, Ward J, Hughes NM et al. Guidelines for clinical target volume definition for perineural spread of major salivary gland cancers. *Clin Oncol* 2018;30:773-779. DOI:10.1016/j.clon.2018.08.018
61. von der Grün J, Rödel C, Semrau S et al. Patterns of care analysis for salivary gland cancer: a survey within the German Society of Radiation Oncology (DEGRO) and recommendations for daily practice. *Strahlenther Onkol* 2022;198:123-134. DOI:10.1007/s00066-021-01833-x
62. Lau VH, Aouad R, Farwell DG, Donald PJ, Chen AM. Patterns of nodal involvement for clinically N0 salivary gland carcinoma: refining the role of elective neck irradiation. *Head & neck*. 2014;36(10):1435-9. DOI:10.1002/hed.23467
63. Chen AM, Garcia J, Lee NY, Bucci MK, Eisele DW. Patterns of nodal relapse after surgery and postoperative radiation therapy for carcinomas of the major and minor salivary glands: what is the role of elective neck irradiation? *Int J Radiat Oncol Biol Phys* 2007;67:988-994. DOI:10.1016/j.ijrobp.2006.10.044
64. Hsieh CE, Lee LY, Chou YC et al. Nodal failure patterns and utility of elective nodal irradiation in submandibular gland carcinoma treated with postoperative radiotherapy - a multi-center experience. *Radiat Oncol* 2018;13:184. DOI:10.1186/s13014-018-1130-y
65. Joshi NP, Broughman JR. Postoperative management of salivary gland tumors. *Curr Treat Options Oncol* 2021;22:23. doi: 10.1007/s11864-021-00820-9. DOI:10.1007/s11864-021-00820-9

66. Terhaard CH, Lubsen H, Rasch CR et al. The role of radiotherapy in the treatment of malignant salivary gland tumors. *Int J Radiat Oncol Biol Phys* 2005;61:103-111. DOI:10.1016/j.ijrobp.2004.03.018
67. Garden AS, Weber RS, Morrison WH, Ang KK, Peters LJ. The influence of positive margins and nerve invasion in adenoid cystic carcinoma of the head and neck treated with surgery and radiation. *Int J Radiat Oncol Biol Phys* 1995;32:619-26. DOI:10.1016/0360-3016(95)00122-f
68. Haderlein M, Scherl C, Semrau S et al. Salivary gland carcinoma (SGC) with perineural spread and/or positive resection margin - high locoregional control rates after photon (chemo) radiotherapy - experience from a monocentric analysis. *Radiat Oncol* 2019;14:68. DOI:10.1186/s13014-019-1260-x
69. Amini A, Waxweiler TV, Brower JV et al. Association of adjuvant chemoradiotherapy vs radiotherapy alone with survival in patients with resected major salivary gland carcinoma: data from the National Cancer Data Base. *JAMA Otolaryngol Head Neck Surg* 2016;142:1100-1110. DOI:10.1001/jamaoto.2016.2168
70. Kang NW, Kuo YH, Wu HC, Ho CH, Chen YC, Yang CC. No survival benefit from adding chemotherapy to adjuvant radiation in advanced major salivary gland cancer. *Sci Rep* 2022;12:20862. DOI:10.1038/s41598-022-25468-9
71. Gordon AJ, Chow MS, Patel A et al. Adoption of adjuvant chemotherapy in high-risk salivary gland malignancies. *Head Neck* 2023;45:167-177. DOI:10.1002/hed.27222
72. Hsieh CE, Lin CY, Lee LY et al. Adding concurrent chemotherapy to postoperative radiotherapy improves locoregional control but Not overall survival in patients with salivary gland adenoid cystic carcinoma-a propensity score matched study. *Radiat Oncol* 2016;11:47. DOI:10.1186/s13014-016-0617-7
73. Schoenfeld JD, Sher DJ, Norris CM Jr et al. Salivary gland tumors treated with adjuvant intensity-modulated radiotherapy with or without concurrent chemotherapy. *Int J Radiat Oncol Biol Phys* 2012;82:308-314. DOI:10.1016/j.ijrobp.2010.09.042
74. Hanna GJ, Bae JE, Lorch JH, Haddad RI et al. The benefits of adjuvant trastuzumab for HER-2-positive salivary gland cancers. *Oncologist* 2020;25:598-608. DOI:10.1634/theoncologist.2019-0841
75. van Boxtel W, Locati LD, van Engen-van Grunsven ACH et al. Adjuvant androgen deprivation therapy for poor-risk, androgen receptor-positive salivary duct carcinoma. *Eur J Cancer* 2019;110:62-70. DOI:10.1016/j.ejca.2018.12.035
76. Mendenhall WM, Morris CG, Amdur RJ, Werning JW, Hinerman RW, Villaret DB. Radiotherapy alone or combined with surgery for adenoid cystic carcinoma of the head and neck. *Head Neck* 2004;26:154-162.
77. Mendenhall WM, Morris CG, Amdur RJ, Werning JW, Villaret DB. Radiotherapy alone or combined with surgery for salivary gland carcinoma. *Cancer* 2005;103:2544-2550. DOI:10.1002/hed.10380
78. Aljabab S, Lui A, Wong T, Liao J, Laramore G, Parvathaneni U. A combined neutron and proton regimen for advanced salivary tumors: early clinical experience. *Cureus* 2021;13:e14844. DOI:10.7759/cureus.14844
79. Jensen AD. Particle therapy: protons and heavy ions. *Adv Otorhinolaryngol* 2020;84:87-105. DOI:10.1159/000457929
80. Cerda T, Sun XS, Vignot S et al. A rationale for chemoradiation (vs radiotherapy) in salivary gland cancers? On behalf of the REFCOR (French rare head and neck cancer network). *Crit Rev Oncol Hematol* 2014;91:142-158. DOI:10.1016/j.critrevonc.2014.02.002

81. Geiger JL, Ismaila N, Beadle B et al. Management of salivary gland malignancy: ASCO guideline. *J Clin Oncol* 2021;39:1909-1941. DOI:10.1200/JCO.21.00449
82. Di Villeneuve L, Souza IL, Tolentino FDS, Ferrarotto R, Schvartsman G. Salivary gland carcinoma: novel targets to overcome treatment resistance in advanced disease. *Front Oncol* 2020;10:580141. DOI:10.3389/fonc.2020.580141
83. Nachtsheim L, Prinz J, Arolt C et al. Neue Therapieansätze für Speicheldrüsenmalignome. *Laryngorhinootologie* 2022;101:876-881. doi: 10.1055/a-1792-2246. DOI:10.1055/a-1792-2246
84. van der Wal JE, Becking AG, Snow GB, van der Waal I. Distant metastases of adenoid cystic carcinoma of the salivary glands and the value of diagnostic examinations during follow-up. *Head Neck* 2002;24:779-783. DOI:10.1002/hed.10126
85. Fang Q, Wu J, Du W, Zhang X. Predictors of distant metastasis in parotid acinic cell carcinoma. *BMC Cancer* 2019;19:475. DOI:10.1186/s12885-019-5711-4
86. Su YX, Roberts DB, Hanna EY et al. Risk factors and prognosis for myoepithelial carcinoma of the major salivary glands. *Ann Surg Oncol* 2015;22:3701-3707. DOI:10.1245/s10434-015-4389-3
87. Even C, Baste N, Classe M. New approaches in salivary gland carcinoma. *Curr Opin Oncol* 2019;31:169-174. DOI:10.1097/CCO.0000000000000527
88. Niwa K, Kawakita D, Nagao T et al. Multicentre, retrospective study of the efficacy and safety of nivolumab for recurrent and metastatic salivary gland carcinoma. *Sci Rep* 2020;10:16988. DOI:10.1038/s41598-020-73965-6
89. Vos JL, Burman B, Jain S et al. Nivolumab plus ipilimumab in advanced salivary gland cancer: a phase 2 trial. *Nat Med* 2023;29:3077-3089. DOI:10.1038/s41591-023-02518-x
90. Airoidi M, Pedani F, Succo G et al. Phase II randomized trial comparing vinorelbine versus vinorelbine plus cisplatin in patients with recurrent salivary gland malignancies. *Cancer* 2001;91:541-547. DOI:10.1002/1097-0142(20010201)91:3<541::aid-cnrc1032>3.0.co;2-y
91. Chintakuntlawar AV, Okuno SH, Price KA. Systemic therapy for recurrent or metastatic salivary gland malignancies. *Cancers Head Neck*. 2016;1:11. DOI:10.1186/s41199-016-0011-z
92. Nakano K, Sato Y, Sasaki T et al. Combination chemotherapy of carboplatin and paclitaxel for advanced/metastatic salivary gland carcinoma patients: differences in responses by different pathological diagnoses. *Acta Otolaryngol* 2016;136:948-951. DOI:10.3109/00016489.2016.1170876
93. Laurie SA, Ho AL, Fury MG, Sherman E, Pfister DG. Systemic therapy in the management of metastatic or locally recurrent adenoid cystic carcinoma of the salivary glands: a systematic review. *Lancet Oncol* 2011;12:815-824. DOI:10.1016/s1470-2045(10)70245-x
94. Licitra L, Marchini S, Spinazzè S et al. Cisplatin in advanced salivary gland carcinoma. A phase II study of 25 patients. *Cancer* 1991;68:1874-1877. DOI:10.1002/1097-0142(19911101)68:9<1874::aid-cnrc2820680904>3.0.co;2-s
95. Vermorken JB, Verweij J, de Mulder PH et al. Epirubicin in patients with advanced or recurrent adenoid cystic carcinoma of the head and neck: a phase II study of the EORTC Head and Neck Cancer Cooperative Group. *Ann Oncol* 1993;4:785-788. DOI:10.1093/oxfordjournals.annonc.a058665
96. Hong DS, DuBois SG, Kummar S et al. Larotrectinib in patients with TRK fusion-positive solid tumours: a pooled analysis of three phase 1/2 clinical trials. *Lancet Oncol* 2020;21:531-540. DOI:10.1016/S1470-2045(19)30856-3

97. Doebele RC, Drilon A, Paz-Ares L et al. Entrectinib in patients with advanced or metastatic NTRK fusion-positive solid tumours: integrated analysis of three phase 1-2 trials. *Lancet Oncol* 2020;21:271-282. DOI:10.1016/S1470-2045(19)30691-6
98. Solomon JP, Linkov I, Rosado A et al. NTRK fusion detection across multiple assays and 33,997 cases: diagnostic implications and pitfalls. *Mod Pathol* 2020;33:38-46. DOI:10.1038/s41379-019-0324-7
99. Takahashi H, Tada Y, Saotome T et al. Phase II trial of trastuzumab and docetaxel in patients with human epidermal growth factor receptor 2-positive salivary duct carcinoma. *J Clin Oncol* 2019;37:125-134. DOI:10.1200/jco.18.00545
100. Jhaveri KL, Wang XV, Makker V et al. Ado-trastuzumab emtansine (T-DM1) in patients with HER2-amplified tumors excluding breast and gastric/gastroesophageal junction (GEJ) adenocarcinomas: results from the NCI-MATCH trial (EAY131) subprotocol Q. *Ann Oncol* 2019;30:1821-1830. DOI:10.1093/annonc/mdz291
101. Li BT, Shen R, Buonocore D et al. Ado-trastuzumab emtansine for patients with HER2-mutant lung cancers: results from a phase II basket trial. *J Clin Oncol* 2018;36:2532-2537. DOI:10.1200/jco.2018.77.9777
102. Takahashi K, Ishibashi E, Kubo T et al. A phase 2 basket trial of combination therapy with trastuzumab and pertuzumab in patients with solid cancers harboring human epidermal growth factor receptor 2 amplification (JUPITER trial). *Medicine* 2020;99:e21457. DOI:10.1097/md.00000000000021457
103. Meric-Bernstam F, Makker V, Oaknin A et al. Efficacy and safety of trastuzumab deruxtecan in patients with HER2-expressing solid tumors: primary results from the DESTINY-Pan-Tumor02 phase II trial. *J Clin Oncol* 2024;42:47-58. DOI:10.1200/jco.23.02005
104. Subbiah V, Wolf J, Konda B et al. Tumour-agnostic efficacy and safety of selpercatinib in patients with RET fusion-positive solid tumours other than lung or thyroid tumours (LIBRETTO-001): a phase 1/2, open-label, basket trial. *Lancet Oncol* 2022;23:1261-1273. DOI:10.1016/s1470-2045(22)00541-1
105. Ross JS, Gay LM, Wang K et al. Comprehensive genomic profiles of metastatic and relapsed salivary gland carcinomas are associated with tumor type and reveal new routes to targeted therapies. *Ann Oncol* 2017;28:2539-2546. DOI:10.1093/annonc/mdx399
106. Lin VTG, Nabell LM, Spencer SA, Carroll WR, Harada S, Yang ES. First-line treatment of widely metastatic BRAF-mutated salivary duct carcinoma with combined BRAF and MEK inhibition. *J Natl Compr Canc Netw* 2018;16:1166-1170. DOI:10.6004/jnccn.2018.7056
107. Tchekmedyian V, Sherman EJ, Dunn L et al. Phase II study of lenvatinib in patients with progressive, recurrent or metastatic adenoid cystic carcinoma. *J Clin Oncol* 2019;37:1529-37. DOI:10.1200/jco.18.01859
108. Locati LD, Perrone F, Cortelazzi B et al. A phase II study of sorafenib in recurrent and/or metastatic salivary gland carcinomas: translational analyses and clinical impact. *Eur J Cancer* 2016;69:158-65. DOI:10.1016/j.ejca.2016.09.022
109. Ho AL, Dunn L, Sherman EJ et al. A phase II study of axitinib (AG-013736) in patients with incurable adenoid cystic carcinoma. *Ann Oncol* 2016;27:1902-1908. DOI:10.1093/annonc/mdw287
110. Kang EJ, Ahn MJ, Ock CY et al. Randomized phase II study of axitinib versus observation in patients with recurred or metastatic adenoid cystic carcinoma. *Clin Cancer Res* 2021;27:5272-5279. DOI:10.1158/1078-0432.Ccr-21-1061
111. Ferrarotto R, Sousa LG, Feng L et al. Phase II clinical trial of axitinib and avelumab in patients with recurrent/metastatic adenoid cystic carcinoma. *J Clin Oncol* 2023;41:2843-2851. DOI:10.1200/jco.22.02221

112. Mayer M, Wolber P, Prinz J et al. The extent of androgen receptor and HER2 expression allows for targeted therapy in most cases of salivary duct carcinoma: analysis of clinical and histopathological data in a tertiary care center. *Eur Arch Otorhinolaryngol.* 2024 Apr 8. DOI:10.1007/s00405-024-08627-8 (Epub ahead of print)
113. Locati LD, Perrone F, Cortelazzi B et al. Clinical activity of androgen deprivation therapy in patients with metastatic/relapsed androgen receptor-positive salivary gland cancers. *Head Neck* 2016;38:724-731. DOI:10.1002/hed.23940
114. van Boxtel W, Verhaegh GW, van Engen-van Grunsven IA et al. Prediction of clinical benefit from androgen deprivation therapy in salivary duct carcinoma patients. *Int J Cancer* 2020;146:3196-3206. DOI:10.1002/ijc.32795
115. Fushimi C, Tada Y, Takahashi H et al. A prospective phase II study of combined androgen blockade in patients with androgen receptor-positive metastatic or locally advanced unresectable salivary gland carcinoma. *Ann Oncol* 2018;29:979-984. DOI:10.1093/annonc/mdx771
116. Locati LD, Cavalieri S, Bergamini C et al. Abiraterone acetate in patients with castration-resistant, androgen receptor-expressing salivary gland cancer: a phase II trial. *J Clin Oncol* 2021;39:4061-4068. DOI:10.1200/jco.21.00468
117. Ho AL, Foster NR, Zoroufy AJ et al. Phase II study of enzalutamide for patients with androgen receptor-positive salivary gland cancers (Alliance A091404). *J Clin Oncol* 2022;40:4240-4249. DOI:10.1200/jco.22.00229
118. Kawakita D, Nagao T, Takahashi H et al. Survival benefit of HER2-targeted or androgen deprivation therapy in salivary duct carcinoma. *Ther Adv Med Oncol* 2022;14:17588359221119538. DOI:10.1177/17588359221119538
119. Gounder M, Ratan R, Alcindor T et al. Nirogacestat, a γ -secretase inhibitor for desmoid tumors. *N Engl J Med* 2023;388:898-912. DOI:10.1056/NEJMoa2210140
120. van Boxtel W, Uijen MJM, Krens SD et al. Excessive toxicity of cabozantinib in a phase II study in patients with recurrent and/or metastatic salivary gland cancer. *Eur J Cancer* 2022;161:128-137. DOI:10.1016/j.ejca.2021.10.033
121. Kapoor A, Noronha V, Chougule A et al. Molecular tumor board: Case 4 Salivary Gland Cancer: Novel therapeutic options as a result of comprehensive molecular profiling. *Cancer Res Stat Treat* 2020;3:554-563. DOI:10.4103/crst.Crst_258_20
122. Gillespie MB, Albergotti WG, Eisele DW. Recurrent salivary gland cancer. *Curr Treat Options Oncol* 2012;13:58-70. DOI:10.1007/s11864-011-0174-0
123. Karam SD, Snider JW, Wang H et al. Reirradiation of recurrent salivary gland malignancies with fractionated stereotactic body radiation therapy. *J Radiat Oncol* 2012;1:147-153. DOI:10.1007/s13566-012-0010-6
124. Vischioni B, Dhanireddy B, Severo C et al. Reirradiation of salivary gland tumors with carbon ion radiotherapy at CNAO. *Radiother Oncol* 2020;145:172-177. DOI:10.1016/j.radonc.2020.01.004
125. Lorini L, Ardighieri L, Bozzola A et al. Prognosis and management of recurrent and/or metastatic head and neck adenoid cystic carcinoma. *Oral Oncol* 2021;115:105213. DOI:10.1016/j.oraloncology.2021.105213
126. Girelli L, Locati L, Galeone C et al. Lung metastasectomy in adenoid cystic cancer: Is it worth it? *Oral Oncol* 2017;65:114-118. DOI:10.1016/j.oraloncology.2016.10.018
127. Franzese C, Ingargiola R, Tomatis S et al. Metastatic salivary gland carcinoma: A role for stereotactic body radiation therapy? A study of AIRO-Head and Neck working group. *Oral Dis* 2022;28:345-351. DOI:10.1111/odi.13755

128. Surun A, Schneider DT, Ferrari A et al. Salivary gland carcinoma in children and adolescents: The EXPeRT/PARTNER diagnosis and treatment recommendations. *Pediatr Blood Cancer* 2021;68 Suppl 4:e29058. DOI:10.1002/pbc.29058
129. Schneider DT, Brecht I: Tumoren der Speicheldrüsen - Kurzinformation. https://www.gpoh.de/kinderkrebsinfo/content/index_ger.html (2023). Accessed 20-JAN-2024.
130. RTOG-1008. A randomized phase II/phase III study of adjuvant concurrent radiation and chemotherapy versus radiation alone in resected high-risk malignant salivary gland tumors. <https://www.nrgoncology.org/Clinical-Trials/Protocol/rtog-1008?filter=rtog-1008>

10 Active studies

- The *Radiation Therapy Oncology Group* 1008 (RTOG-1008) is investigating the role of adjuvant radiochemotherapy with cisplatin versus radiotherapy in operated *high-risk* salivary gland carcinoma with a 4-year follow-up in a randomized phase II/III trial (ClinicalTrials.gov identifier NT01220583). Recruitment was completed in March 2021. The study protocol can be found here: [130].
- The GORTEC 2016-02 Phase III SANTAL trial compares postoperative radiotherapy with radiochemotherapy with cisplatin in patients with operated salivary gland carcinoma and paranasal sinus carcinoma. The trial was started in 2017 and is scheduled to be completed in 2030 (ClinicalTrials.gov identifier **NCT02998385**).
- The EORTC HNCG/UKCRN 1206 study "randomized phase II study to evaluate the efficacy and safety of chemotherapy (CT) vs androgen deprivation therapy (ADT) in patients with recurrent and/or metastatic androgen receptor (AR) expressing SGC" is investigating the effect of antiandrogen therapy in androgen receptor positive salivary duct carcinoma or adenocarcinoma NOS (ClinicalTrials.gov identifier NCT01969578). The trial is scheduled to be completed in mid-2024.
- Led by Dana-Farber Cancer Institute with sponsorship from Genentech, Inc.A, started a multicenter phase II study on adjuvant combination therapy with ado-trastuzumab emtansine (T-DM1) in HER2-positive salivary gland carcinomas during and after postoperative radiotherapy in 2020: "Phase II Study of Adjuvant Ado-trastuzumab Emtansine (T-DM1) in HER2-positive Salivary Gland Carcinomas"; anticipated completion: 01 February 2026 (ClinicalTrials.gov Identifier NCT04620187).

15 Authors' Affiliations

Prof. Dr. med. Dr. med. dent. Benedicta Beck-Broichsitter

Klinikum Stuttgart, Katharinenhospital
 Klinik für Mund-, Kiefer- und Gesichtschirurgie
 Kriegsbergstr. 60
 70174 Stuttgart
b.beck-broichsitter@klinikum-stuttgart.de

Assoc. Prof. PD Dr. Thorsten Füreder

Medizinische Universität Wien
 Universitätsklinik f. Innere Medizin I
 Klinische Abteilung für Onkologie
 Währinger Gürtel 18-20
 AT-1090 Wien
thorsten.fuereder@meduniwien.ac.at

Prof. Dr. med. Orlando Guntinas-Lichius

Universitätsklinikum Jena
Klinik für Hals-, Nasen- und Ohrenheilkunde
Kastanienstr. 1
07747 Jena
orlando.Guntinas@med.uni-jena.de

PD Dr. med. Marlen Haderlein

Universitätsklinikum Erlangen
Strahlenklinik
Universitätsstrasse 27
91054 Erlangen
marlen.haderlein@uk-erlangen.de

Prof. Dr. med. Stephan Ihrler

DERMPATH München
Bayerstr. 69
80335 München
ihrler@dermpath-muenchen.de

Gunthard Kissinger

Selbsthilfenetzwerk Kopf-Hals-M.U.N.D.-Krebs e.V.
Thomas-Mann-Straße 40
53111 Bonn
gunthard.kissinger@kopf-hals-mund-krebs.de

PD Dr. med. Konrad Klinghammer

Charité Universitätsmedizin Berlin
Medizinische Klinik mit Schwerpunkt Hämatologie,
Onkologie und Tumorummunologie (CBF)
Hindenburgdamm 30
12203 Berlin
konrad.klinghammer@charite.de

Prof. Dr. med. Jens-Peter Klußmann

Universitätsklinikum Köln
Klinik und Poliklinik für Hals-, Nasen- und Ohrenheilkunde
Kerpener Str. 62
50937 Köln
jens.klussmann@uk-koeln.de

Dr. med. Florian Kocher

Medizinische Universität Innsbruck
Universitätsklinik für Innere Medizin V
Anichstr. 35
A-6020 Innsbruck
florian.kocher@i-med.ac.at

Prof. Dr. Nicolas Mach

Médecin Adjoint Agrégé
Service d'Oncologie
Hôpitaux Universitaires de Genève
Rue Gabrielle-Perret-Gentil 4
CH-1205 Genf
nicolas.mach@hug.ch

PD Dr. med. Moritz Friedo Meyer

Universitätsklinikum Essen
Klinik für Hals-Nasen-Ohrenheilkunde, Kopf- und Halschirurgie
Hufelandstr. 55
45147 Essen
moritz.meyer@uk-essen.de

Prof. Dr. med. Marc Münter

Klinikum Stuttgart - Katharinenhospital
Klinik für Strahlentherapie und Radioonkologie
Kriegsbergstraße 60
70174 Stuttgart
m.muenter@klinikum-stuttgart.de

PD Dr. med. Timothée Olivier

Médecin Adjoint Agrégé
Service d'Oncologie
Hôpitaux Universitaires de Genève
Rue Gabrielle-Perret-Gentil 4
CH-1205 Genf
timothee.olivier@hug.ch

Dr. med. Philippe Schafhausen

Universitätskrankenhaus Eppendorf
II. Medizinische Klinik, UCCH,
Onkologie und Hämatologie
Martinistr. 52
20246 Hamburg
schafhausen@uke.de

Prof. Dr. med. Thomas J. Vogl

Universitätsklinikum Frankfurt/M.
Klinik für Radiologie und Nuklearmedizin
Theodor-Stern-Kai 7
60590 Frankfurt am Main
t.vogl@em.uni-frankfurt.de

Prof. Dr. med. Barbara Wollenberg

Klinikum rechts der Isar der Technischen Universität München
Klinik und Poliklinik für Hals-, Nasen-, Ohrenheilkunde
Ismaninger Str. 22
81675 München
barbara.wollenberg@mri.tum.de

16 Disclosure of Potential Conflicts of Interest

according to the rules of the responsible Medical Societies.