



# Osteosarcomas

Recommendations from the society for diagnosis and therapy of  
haematological and oncological diseases

---

## **Publisher**

DGHO Deutsche Gesellschaft für Hämatologie und  
Medizinische Onkologie e.V.

Bauhofstr. 12  
D-10117 Berlin

Executive chairwoman: Prof. Dr. med. Claudia Baldus

Phone: +49 (0)30 27 87 60 89 - 0

[info@dgho.de](mailto:info@dgho.de)

[www.dgho.de](http://www.dgho.de)

## **Contact person**

Prof. Dr. med. Bernhard Wörmann  
Medical superintendent

## **Source**

[www.onkopedia-guidelines.info](http://www.onkopedia-guidelines.info)

The information of the DGHO Onkopedia Web Site is not intended or implied to be a substitute for professional medical advice or medical care. The advice of a medical professional should always be sought prior to commencing any form of medical treatment. To this end, all component information contained within the web site is done so for solely educational purposes. DGHO Deutsche Gesellschaft für Hämatologie und Onkologie and all of its staff, agents and members disclaim any and all warranties and representations with regards to the information contained on the DGHO Web Site. This includes any implied warranties and conditions that may be derived from the aforementioned web site information.

# Table of contents

<b>1 Summary</b>	<b>2</b>
<b>2 Basics</b>	<b>2</b>
2.1 Definition and basic information	2
2.2 Epidemiology	2
2.3 Pathogenesis	3
2.4 Risk factors	4
<b>3 Prevention and early detection</b>	<b>4</b>
<b>4 Clinical characteristics</b>	<b>4</b>
<b>5 Diagnosis</b>	<b>4</b>
5.1 Diagnostic procedures	4
5.2 Classification	5
5.2.1 Histological subtypes	5
5.2.2 Staging	6
<b>6 Therapy</b>	<b>8</b>
6.1 Treatment structure	8
6.1.1 First-line therapy	9
6.1.1.1 Low-grade osteosarcomas	9
6.1.1.2 Periosteal osteosarcoma	9
6.1.1.3 High-grade osteosarcoma	10
6.1.1.3.1 Chemotherapy	10
6.1.1.3.1.1 Patients up to 40 years of age	10
6.1.1.3.1.2 Patients older than 40 years	11
6.1.1.4 High-grade craniofacial osteosarcoma/jaw osteosarcoma	11
6.2 Local therapy	12
6.2.1 Surgery	12
6.2.2 Radiotherapy	12
6.2.3 Local therapy of metastases	13
6.3 Special settings	13
6.3.1 Recurrence	13
6.3.1.1 Potentially resectable disease	13
6.3.1.2 Non-resectable disease	13
<b>7 Rehabilitation</b>	<b>14</b>
<b>8 Follow-up</b>	<b>14</b>
<b>9 References</b>	<b>14</b>
<b>15 Authors' Affiliations</b>	<b>18</b>
<b>16 Disclosures</b>	<b>20</b>

# Osteosarcomas

**Date of document:** January 2023

**Compliance rules:**

- [Guideline](#)
- [Conflict of interests](#)

**Authors:** Lars H. Lindner, Dimosthenis Andreou, Sebastian Bauer, Stefan Bielack, Matthias Grube, Wolfgang Hartmann, Stefanie Hecker-Nolting, Attila Kollár, Klaus Kraywinkel, Joanna Szkandera, Beate Timmermann, Per Ulf Tunn, Klaus Wörtler

## 1 Summary

Osteosarcoma is the most common malignant bone tumor and is characterized by early micrometastasis. The introduction of systemic chemotherapy in addition to tumor resection has significantly improved the prognosis of patients [1, 2]. Therefore, multimodal therapy using neoadjuvant chemotherapy followed by wide tumor resection and adjuvant chemotherapy is now considered the standard of care. Thus, 5-year survival rates of 70% can be achieved [3]. Possible primary metastases must additionally be surgically removed if the goal of therapy is curative. High-dose radiotherapy is indicated only in case of incomplete tumor resection. In case of recurrence, complete metastasectomy has the highest priority. Second-line chemotherapy for patients in second surgical remission is frequently performed but is not yet supported by prospective studies.

## 2 Basics

### 2.1 Definition and basic information

Osteosarcoma is a mesenchymal tumor disease characterized by the formation of immature bone substance (osteoid). Hematogenous metastasis must be assumed even at initial diagnosis. Predilection sites are the metaphyses of the long tubular bones (especially the knee region with distal femur and proximal tibia, but also the distal humerus), while involvement of the spine and pelvic skeleton is less common. In most patients, only a singular primary tumor lesion occurs [4- 6].

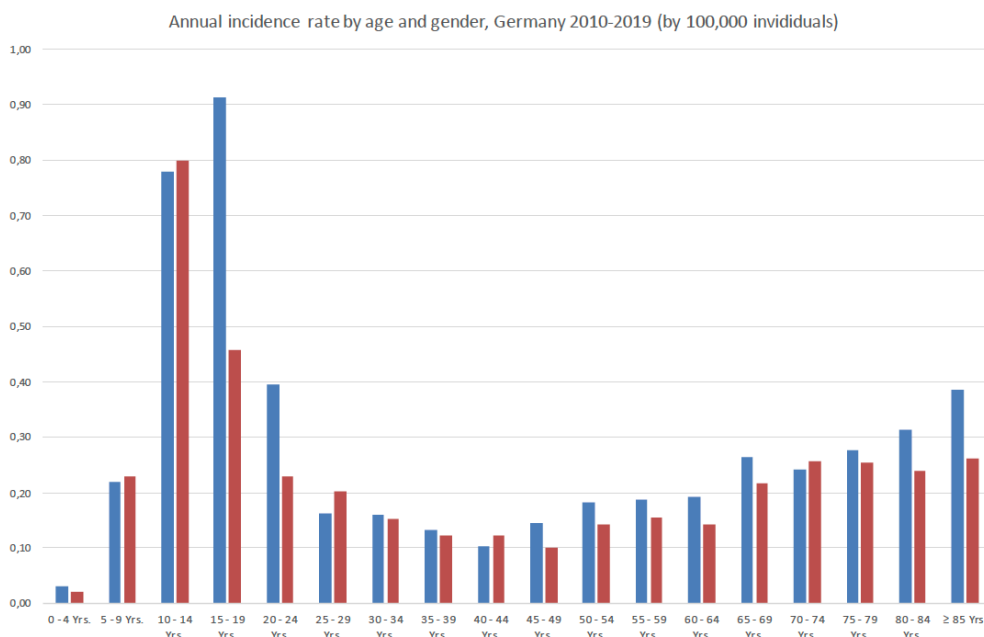
### 2.2 Epidemiology

Osteosarcoma is rare, with an annual incidence of about 0,2-0,3 per 100,000 persons (crude incidence rate). In Germany, 1934 cases were recorded in the regional cancer registries or the German Childhood Cancer Registry nationwide between 2010 and 2019, of which 885 occurred in women and girls. The disease accounts for just under a quarter of malignant tumors of bone. A clear age peak is in the 2nd decade, where osteosarcoma represents more than half of malignant bone tumors. In European registries, another incidence peak is found in the 7th and 8th decades of life [7]. The overall slightly higher incidence in males results mainly from the significantly higher incidence rates between the ages of 15 and 24 years (Figure 1). Accordingly, the median age at onset in men (30 years) is significantly lower than in women (40 years).

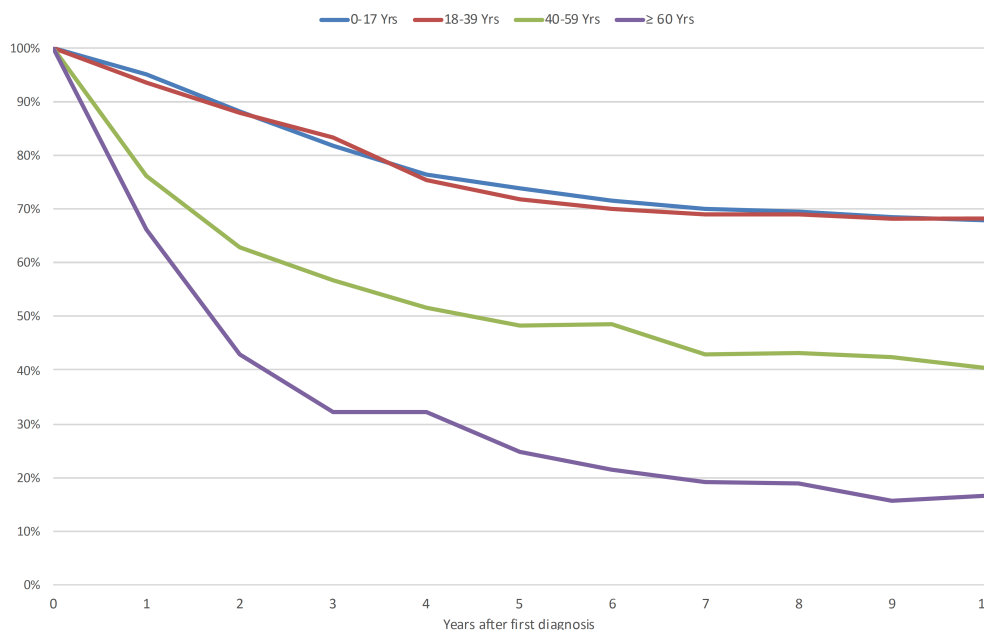
Slightly more than half of the cases involve the long tubular bones of the lower extremity, with this proportion exceeding 70% in childhood and adolescence and declining progressively with age. Relative 10-year survival rates are around 68% in both children and adolescents as well as

in young adults (up to 39 years) and decrease significantly in middle and older adulthood (40-65 years, 40%, 65 years and older, 15%) (Figure 2).

**Figure 1: Annual incidence rates of osteosarcoma in Germany by age and gender (per 100,000 persons, 2010-2019)**



**Figure 2: Relative survival rates after diagnosis of osteosarcoma in Germany, by age group, period 2015-2019\***



Legend:

\* Results for the age group 0-17 years provided by the German Childhood Cancer Registry (2010-2019)

## 2.3 Pathogenesis

Osteosarcoma is a usually highly aggressive bone-derived sarcoma originating from pluripotent mesenchymal progenitor cells. Conventional osteosarcomas are mostly characterized by high genomic instability with complex karyotype and numerous numerical and structural aberrations [8]. Alterations in TP53 and RB1 are the most common recurrent aberrations. Approximately 80% of osteosarcomas have additional alterations that are also found in cancers with homologous recombination repair deficiency [9].

## 2.4 Risk factors

There are several known risk factors for the emergence of osteosarcoma:

- **Ionizing radiation** (typical time interval 12-16 years).
- **Chemotherapy** (especially alkylating substances)
- **Paget's disease** (in patients > 40 years)
- **Genetic predisposition syndrome** (e.g., RB1 mutation in retinoblastoma, TP53 mutation in Li-Fraumeni syndrome, RECQL4 mutation in Rothmund-Thomson syndrome, RECQL4 mutation in RAPADILINO syndrome, and BLM and WRN mutations in Bloom and Werner syndromes).

## 3 Prevention and early detection

There is no evidence of effective measures for prevention and early detection in the general population. Individuals with known hereditary predisposition are excluded.

## 4 Clinical characteristics

The leading symptom is pain in the affected region, which often lasts for weeks and is load-independent. In addition, there may be swelling or functional impairment. In about 10% of cases, a pathologic fracture is already present at first diagnosis [10]. General symptoms such as fever, weight loss, or a decreased general condition are usually lacking.

In osteosarcomas of the jaw, loosening of teeth and swelling may be early symptoms.

In approximately 10-20% of patients, macrometastases can already be detected at initial staging. The target organ is most frequently the lung, followed by the bones. In the remaining 80-90% of patients, micrometastasis must be assumed at initial diagnosis. Detection of metastasis at first diagnosis results in a worse prognosis [11].

## 5 Diagnosis

### 5.1 Diagnostic procedures

Careful history taking and complete physical examination are the basis of rational diagnostics. The following diagnostic measures are recommended (see Tables 1-3).

**Table 1: Diagnostic procedures for new-onset symptoms**

- X-rays of the affected bone and adjacent joints in 2 planes
- Magnetic resonance imaging (MRI) of local findings according to standardized protocol\*.
- Biopsy\*\*

*Legend:*

*\*Initial diagnosis, MRI must include T1-weighted imaging of the entire tumor-bearing bone in the long axis to detect or exclude skip lesions. Subsequently, the scan should switch to a high-resolution coil and image the tumor with the adjacent joint (small imaging field) to accurately visualize local tumor spread. The slice orientation in the long axis depends on the anatomy of the adjacent joint (coronal at wrist, shoulder and hip joint, sagittal at knee and ankle). The following pulse sequences must be performed as a minimum:*

*Long axis: STIR, T1-weighted before and after intravenous contrast administration (incl. image subtraction)*

*Short axis: T2-weighted, T1-weighted with fat suppression after intravenous contrast administration*

*\*\*Biopsy can be performed as punch biopsy or open biopsy. It is important that sufficient material is obtained and that a surgeon experienced in bone sarcoma therapy is involved in the diagnosis from the beginning.*

If the suspected diagnosis of osteosarcoma is confirmed on biopsy, staging is indicated (see [Table 2](#)). It is based on the most frequent localizations of metastases in patients with osteosarcoma.

**Table 2: Staging procedures**

<ul style="list-style-type: none"> <li>• Thoracic computed tomography (CT)</li> <li>• Bone scintigram or alternatively whole-body FDG-Positron Emission Tomography/CT or FDG-PET/MRI</li> </ul>
---

**Table 3: Optional diagnostic procedures**

<p><b>Laboratory</b></p> <ul style="list-style-type: none"> <li>• CBC and leukocyte differentiation</li> <li>• Serum chemistry (incl. alkaline phosphatase and lactate dehydrogenase)</li> <li>• Coagulation parameters</li> <li>• Virology (hepatitis A-C, HIV)</li> </ul>
<p><b>Functional diagnostics</b></p> <ul style="list-style-type: none"> <li>• Echocardiography, ECG</li> <li>• Creatinine clearance</li> <li>• Audiometry</li> <li>• Pulmonary function diagnostics in case of pulmonary metastases</li> </ul>

No specific laboratory biomarkers exist for osteosarcoma. Certain parameters should be determined before or also in the course of neo- and adjuvant chemotherapy.

Functional diagnostic tests are used to assess treatment feasibility before or to assess organ toxicities during chemotherapy. For patients with the desire for children, fertility-preserving measures should be discussed at an early stage and carried out if necessary.

## 5.2 Classification

### 5.2.1 Histological subtypes

Histological classification is based on the current WHO classification for tumors of soft tissue and bone (2020). Most osteosarcomas are highly malignant tumors (high grade; G3), but cases of intermediate (G2) or low malignancy (G1) also occur (see [Table 4](#)).

The most common are the highly malignant conventional osteosarcomas (80-90%), which arise in the medullary cavity of the bone (intramedullary). Parosteal and periosteal osteosarcomas arise from the bone surface.

Extraskeletal osteosarcomas are classified as soft tissue sarcomas according to the WHO classification.

Rarely, multifocal osteosarcoma may occur. In this case, it is difficult to distinguish whether the lesions are multiple, synchronous, primary osteosarcomas or metastases.

Secondary osteosarcomas occur, for example, in the context of Paget's disease of the bone or following irradiation.

**Table 4: WHO classification of osteosarcoma 2020 (modified)**

Malignancy grade	Osteosarcoma subtype
Grade 1 (low-grade)	<ul style="list-style-type: none"><li>• Parosteal osteosarcoma</li><li>• Low-grade malignant central osteosarcoma</li></ul>
Grade 2 (intermediate)	<ul style="list-style-type: none"><li>• Periosteal osteosarcoma</li></ul>
Grade 3 (high-grade)	<ul style="list-style-type: none"><li>• Osteosarcoma with the following subtypes:<ul style="list-style-type: none"><li>◦ Conventional osteosarcoma*</li><li>◦ Teleangiectatic osteosarcoma</li><li>◦ Small cell osteosarcoma</li></ul></li><li>• High-grade malignant surface osteosarcoma</li></ul>

*Legend:*

*\*Conventional osteosarcoma is subdivided into osteoblastic, chondroblastic, and fibroblastic types depending on the histologic pattern. Morphologic variants such as giant cell-rich, osteblastoma-like, or epithelioid osteosarcoma are also attributed to conventional osteosarcoma.*

### **5.2.2 Staging**

Classification of the extent of the primary tumor and metastasis is based on the *American Joint Committee on Cancer* (AJCC) TNM criteria (see [Table 5](#)).

**Table 5: TNM classification of bone tumors**

<b>T - primary tumor</b>	
TX:	Primary tumor cannot be assessed
T0:	No evidence of primary tumor
<i>Extremity skeleton, trunk, skull and facial bones</i>	
T1:	Tumor 8 cm or less in greatest extension
T2:	Tumor more than 8 cm in greatest extension
T3:	Discontinuous spread in the primary affected bone
<i>Spine</i>	
T1:	Tumor limited to a single vertebral segment* or two adjacent vertebral segments
T2:	Tumor limited to three adjacent vertebral segments*.
T3:	Tumor limited to four adjacent vertebral segments*.
T4a:	Tumor infiltrates the spinal canal
T4b:	Tumor infiltrates the great vessels or tumor thrombosis within the great vessels
<i>*the five spinal segments are: right pedicle, right vertebral body, left vertebral body, left pedicle, posterior element.</i>	
<i>Pelvis</i>	
T1a:	Tumor 8 cm or less in greatest extent and confined to a single segment* of the pelvis without extraosseous spread
T1b:	Tumor more than 8 cm in greatest extent and confined to a single segment* of the pelvis without extraosseous spread
T2a:	Tumor 8 cm or less in greatest extent and confined to a single segment* of the pelvis with extraosseous spread or two adjacent segments* of the pelvis without extraosseous spread
T2b:	Tumor more than 8 cm in greatest extent and confined to a single segment* of the pelvis with extraosseous spread or two adjacent segments* of the pelvis without extraosseous spread
T3a:	Tumor 8 cm or less in greatest extent and confined to two adjacent segments* of the pelvis with extraosseous spread
T3b:	Tumor more than 8 cm in greatest extent and confined to two adjacent segments* of the pelvis with extraosseous spread
T4a:	Tumor involving three segments* of the pelvis or crossing the sacroiliac joint into the sacral neuroforamen
T4b:	Tumor encircles the external iliac vessels or macroscopically demonstrable tumor thrombosis in large iliac vessels
<i>*the four pelvic segments are: Os sacrum, pelvic scapula, acetabulum/periacetabulum and pelvic branches, symphysis.</i>	
<b>N - Regional lymph nodes</b>	
NX:	Regional lymph nodes cannot be assessed
N0:	No regional lymph node metastases
N1:	Regional lymph node metastases

<b>M - distant metastases</b>			
M0:	No distant metastases		
M1:	Distant metastases		
M1a:	Pulmonary metastases		
M1b:	Other distant metastases		
<b>Stage grouping (limb skeleton, trunk, skull, facial bones)</b>			
Stage IA	T1	N0 M0	G1/GX Low grade
Stage IB	T2, T3	N0 M0	G1/GX Low grade
Stage IIA	T1	N0 M0	G2, G3 High grade
Stage IIB	T2	N0 M0	G2, G3 High grade
Stage III	T3	N0 M0	G2, G3 High
Stage IVA	Each T	N0 M1a	Each G
Stage IVB	Each T	N1 Each M	Each G
	Each T	Any N M1b	Each G

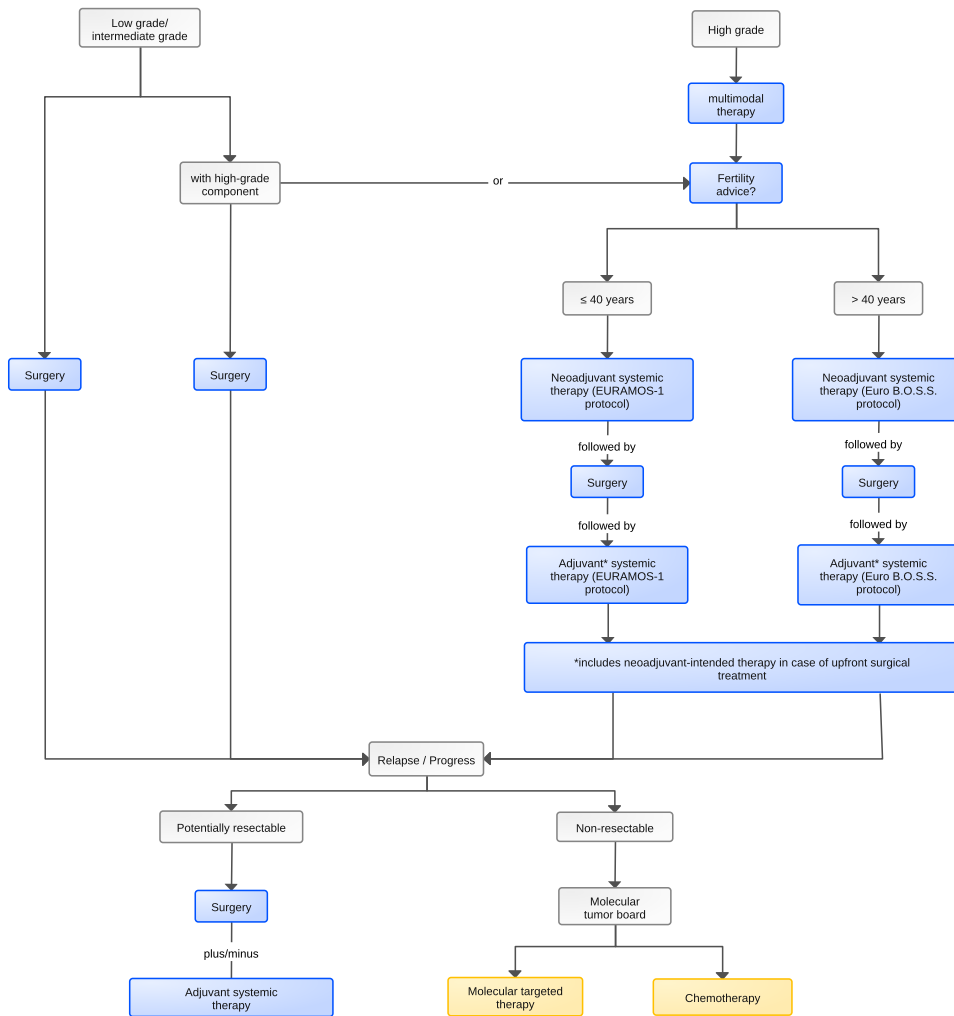
## 6 Therapy

### 6.1 Treatment structure

Treatment decisions for patients with osteosarcoma should be made in a multidisciplinary tumor board and at a center experienced in treating osteosarcoma patients.

In the case of localized high-grade osteosarcoma, occult metastasis must be assumed at the time of initial diagnosis. Therefore, neoadjuvant chemotherapy is usually administered, followed by resection and subsequent adjuvant chemotherapy. If the primary tumor has already been resected, all chemotherapy is adjuvant. The algorithm for first-line therapy is shown in [Figure 3](#).

**Figure 3: Treatment of osteosarcoma**



Legend:

■ = curative intended therapy, ■ = palliative therapy

\*includes additionally neoadjuvant intended therapy, if primary surgery has been performed

### 6.1.1 First-line therapy

#### 6.1.1.1 Low-grade osteosarcomas

In low-grade osteosarcomas (parosteal and low-malignant central osteosarcoma), therapy is primarily surgical due to the low metastatic potential. However, in case of detection of a high-grade component (dedifferentiation), chemotherapy may be considered [12]. Smaller dedifferentiated areas are not yet a clear indication for chemotherapy in low-malignant central osteosarcoma [13, 14].

#### 6.1.1.2 Periosteal osteosarcoma

In patients with periosteal osteosarcoma (intermediate risk), a benefit from chemotherapy has not yet been demonstrated [13- 15].

### 6.1.1.3 High-grade osteosarcoma

#### 6.1.1.3.1 Chemotherapy

The value of chemotherapy for high-grade osteosarcoma from the time of primary diagnosis is unequivocal. Although no survival advantage has been formally shown for neoadjuvant/adjuvant versus adjuvant chemotherapy alone [16], the concept of neoadjuvant/adjuvant chemotherapy is preferred. This is especially true if an improvement in surgical resectability can be achieved by preoperative systemic treatment [6, 17, 18].

Response to neoadjuvant chemotherapy is considered an important prognostic factor. It has been shown that 5-year survival rates are much higher for patients with good histopathologic response ( $\geq 90\%$  necrosis rate) than for patients with lower response (71-80% and 45-60% necrosis rate, respectively) [6][19- 21].

Doxorubicin, cisplatin, high-dose methotrexate (HD-MTX), and ifosfamide have proven antitumor efficacy in osteosarcoma and are used as part of first-line therapy. Different chemotherapy protocols are recommended depending on patient age. HD-MTX at a dose of  $12 \text{ g/m}^2$  is used as a standard regimen only in younger patients ( $\leq 40$  years), due to higher toxicity, and is replaced by ifosfamide in older age groups. In case of poor response to ifosfamide, there is an option to supplement HD-MTX with a slightly lower dose of  $8 \text{ g/m}^2$  (see below).

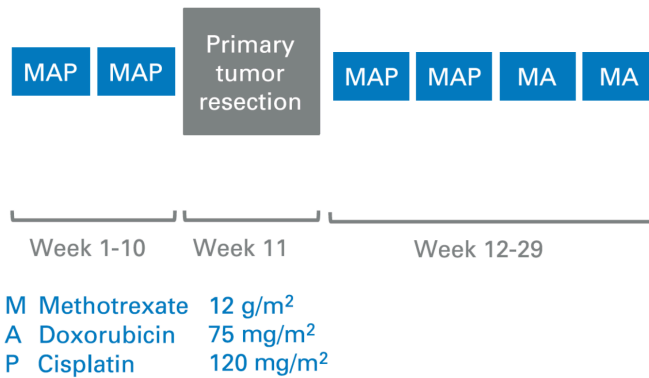
Retrospective data have shown that the time interval between tumor resection and the start of adjuvant chemotherapy has an impact on prognosis [22]. Adjuvant chemotherapy should therefore be started within 21 days of resection, if possible.

Patients in whom metastasis has already been detected at first diagnosis have a worse prognosis than patients with local tumor detection only. Lung metastases are prognostically more favorable than bone metastases. Nevertheless, long-term survival of 10-50% can be achieved even in these patients by multimodal treatment protocols with chemotherapy and resection (primary tumor and metastases) [23- 25]. Regarding the choice of chemotherapy, patients with primary metastatic disease are treated in the same way as patients with localized osteosarcoma.

##### 6.1.1.3.1.1 Patients up to 40 years of age

The treatment in this patient cohort is analogous to the standard arm in the EURAMOS-1 protocol with HD-MTX ( $12 \text{ g/m}^2$ ), doxorubicin and cisplatin (MAP chemotherapy; Figure 4). The first 2 cycles of MAP are neoadjuvant. This is followed postoperatively by 2 additional cycles of MAP and 2 cycles of HD-MTX and doxorubicin (MA). Addition of further agents or intensification of chemotherapy depending on histologic response in the EURAMOS-1 trial had not resulted in improved treatment outcomes, but in increased toxicity [10, 26, 27].

**Figure 4: MAP chemotherapy protocol**

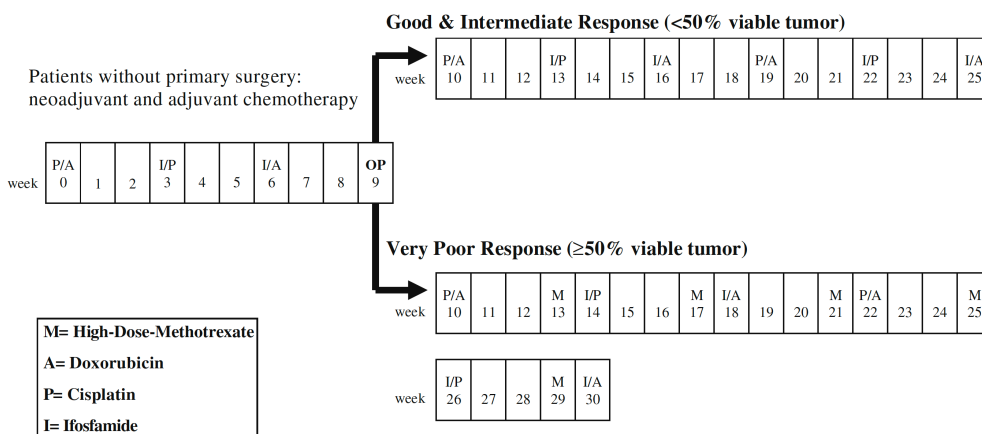


Based on the results of a randomized American trial, which showed an overall survival benefit after the addition of the immunomodulator liposomal muramyl tripeptide phosphatidyl ethanolamine (L-MTP-PE) to postoperative chemotherapy, this agent was approved in combination with chemotherapy for the treatment of completely resected localized osteosarcoma in patients younger than 30 years of age [28]. However, according to various European and American osteosarcoma groups, these data are not sufficient to support the routine use of this agent outside of controlled clinical trials [29].

#### 6.1.1.3.1.2 Patients older than 40 years

Due to the poorer tolerability of HD-MTX in this age group, therapy is analogous to the Euro-B.O.S.S. protocol with doxorubicin, cisplatin, and ifosfamide (Figure 5) [30]. Poor histologic response is also considered a negative prognostic factor for elderly patients. The addition of HD-MTX at a reduced dose (8 g/m<sup>2</sup>) offers an additional option in this case (< 50% necrosis or Salzer-Kuntschik grade 5-6) [30].

**Figure 5: Euro B.O.S.S. protocol**



#### 6.1.1.4 High-grade craniofacial osteosarcoma/jaw osteosarcoma

Although the risk of distant metastasis is considered to be somewhat lower, therapy of high-grade craniofacial osteosarcoma/jaw osteosarcoma should be performed in analogy to high-grade osteosarcoma in other locations [7]. The prognosis after multimodal treatment with pre-operative and/or postoperative chemotherapy is considered good [30- 33]. Because of the localization, which is usually difficult to access surgically, administration of all perioperative chemotherapy in the neoadjuvant setting with close monitoring may prove beneficial [34].

## 6.2 Local therapy

### 6.2.1 Surgery

Surgery should be performed exclusively by surgeons experienced in bone sarcoma surgery who are also proficient in the required reconstructive techniques. Achieving R0 resection is the defined goal of surgery. In most cases, an extremity-preserving approach is possible.

It is desirable to perform the biopsy of an osteosarcoma at the same specialized center where the subsequent tumor resection is to be performed. A large retrospective analysis of data from the Cooperative Osteosarcoma Study Group (COSS) showed that the risk of local recurrence after an out-of-center biopsy is more than twice as high as when the biopsy is performed in the center [35] - a staggering finding considering that the development of local recurrence is associated with a dramatic worsening of the probability of survival. The same analysis further emphasized the importance of treating patients in experienced centers, as limb preservation could be realized in 70% of patients in high-volume clinics compared with 51% in low-volume clinics [35].

Depending on the extent of bone destruction, there is a risk of pathologic fracture, especially in the region of the long tubular bones [35], which may be further increased after open biopsies. To reduce the risk of pathologic fracture in the long tubular bone region during neoadjuvant chemotherapy, temporary lower weight-bearing or even complete unloading of the affected lower extremity may be useful. However, unloading is also associated with muscle atrophy and secondary osteopenia, so it cannot be recommended as a standard. Since there is no established risk score for the development of pathologic fractures, the question of the need for lower weight-bearing or unloading must be discussed individually with the primary orthopedist or trauma surgeon who takes the biopsy.

Taking into account the frequently metaphyseal localization of osteosarcoma in the extremities, defect reconstruction using tumor endoprostheses is preferred, with the advantages of rapid full weight-bearing of the affected limb and a good functional outcome. The 5-year implant survival is 78% for proximal femoral replacement, 65% for distal femoral replacement, and 61% for proximal tibial replacement. The most common reason for secondary amputation is local recurrence (63%) followed by periprosthetic infection (34%) [36].

In very young patients (< 5 years of age), the amputation rate is significantly increased because of limited reconstruction options. In the case of osteosarcomas in the femur and proximal tibia, rotationplasty is a reasonable alternative to amputation or implantation of growth endoprostheses in slightly older children. Rotationplasty is generally a one-time surgical procedure. With the appropriate prosthetic fitting, patients are functionally and emotionally almost in line with the general population [37].

### 6.2.2 Radiotherapy

Radiation therapy may be considered for primary unresectable primary tumors or as adjuvant therapy in cases of high local recurrence risk and lack of options for R0 resection. Osteosarcoma is considered relatively resistant to radiation. Therefore, modern, highly conformal radiotherapy techniques such as IMRT or particle therapy with protons or heavy ions should be considered especially in case of curative intention in order to achieve high local doses. In case of R0 resection, there is no indication for adjuvant radiotherapy. However, radiotherapy can be used in a palliative treatment approach as an alternative to surgery and also symptom-directed therapy of metastases.

### **6.2.3 Local therapy of metastases**

Treatment of patients with primary metastatic osteosarcoma may follow the same principles as in patients without metastasis. In patients with lung metastases only, in whom all foci can be surgically removed, the 5-year survival may be as high as 44%. If other regions were also affected, 5-year survival was only 19% [38]. For palliative treatment of metastases in cases of fracture risk or pain, local radiotherapy may be considered.

Since L-MTP-PE has not resulted in any survival benefit in this group of patients, it should not be used outside of clinical trials in this setting either [39].

## **6.3 Special settings**

### **6.3.1 Recurrence**

Therapy in case of recurrence or metastasis depends on the time interval to primary therapy as well as the number and location of metastases [38]. For example, a preceding disease-free interval of 18 to 24 months, a maximum of 2 pulmonary metastases, and unilateral pulmonary involvement without pleural involvement are considered favorable prognostic factors.

Treatment should preferably be performed at an experienced center.

#### **6.3.1.1 Potentially resectable disease**

Therapy is primarily surgical if complete removal of the local recurrence and/or metastases can be achieved. About 1/3 of patients after 2nd surgical remissions survive longer than 5 years [40]. This is also true for repeated recurrences. If a surgical approach is not possible, alternative procedures such as (stereotactic) radiotherapy, radiofrequency ablation (RFA) or cryotherapy can be used to treat lung metastases [7]. RFA and (stereotactic) radiotherapy can optionally also be used for the therapy of bone metastases [41].

The role of renewed adjuvant chemotherapy after achieving a 2nd surgical remission is not clear. Thus, retrospective analyses showed either no benefit, a benefit only in a subgroup (e.g., patients with  $\geq 3$  pulmonary metastases), or a small benefit [38, 40, 42]. We recommend that in patients with early recurrence (within 12 months), multiple metastases ( $\geq 3$  lung metastases), or pleural involvement, the use of second-line chemotherapy in addition to resection of all manifest tumor sites should be considered. Carboplatin and etoposide, high-dose ifosfamide alone or in combination with etoposide, gemcitabine, and docetaxel [43- 45], and cyclophosphamide and topotecan [46] may be used. Patients with late solitary pulmonary recurrence do not benefit from additional salvage chemotherapy, according to current knowledge [47]. Further treatment in terms of maintenance therapy is not standard of care in second complete remission.

#### **6.3.1.2 Non-resectable disease**

Patients with non-resectable local recurrence or extensive metastasis are treated with palliative intent. In these patients, presentation to a molecular tumor board should be considered.

Depending on the general condition and the chemotherapy given so far, the same therapy regimens as in chapter 6.3.1.1 can be considered. In addition to classical chemotherapeutic agents, the use of molecularly targeted drugs (alone or in combination), for which a prolongation of the progression-free interval has been reported from phase I/II studies, can also be considered (e.g.

sorafenib plus/minus everolimus [48, 49], gemcitabine/sirolimus [50], regorafenib [51, 52] or cabozantinib [53]).

Current studies also focus on the use of immune checkpoint inhibitors (ICI) in patients with advanced or metastatic osteosarcoma. In case of proven microsatellite instability (MSI-H) or mismatch repair deficiency (dMMR) or high tumor mutation burden (TMB-H), treatment with pembrolizumab or nivolumab/ipilimumab may be discussed [54- 56].

## 7 Rehabilitation

Surgery, radiation therapy and systemic tumor therapy can lead to therapy sequelae of varying severity that require targeted rehabilitative measures. In addition, there are the special psychological and social effects of cancer in adolescents and young adults.

Patients should be informed at an early stage about the possibilities of outpatient and inpatient rehabilitation measures as well as other claims arising from social law. With regard to the rehabilitation clinic, the patients' wishes should be taken into account (§9 SGB IX). Nevertheless, a recommendation should be made for a clinic with an oncological focus, which has special experience also in the age group of osteosarcoma patients. Furthermore, experience with patients after major tumor operations of the skeletal system is useful to ensure focussed physiotherapy.

## 8 Follow-up

The aim of follow-up procedures is the early detection of local recurrence or metastasis with the possibility of initiating specific therapy as early as possible, as well as the detection of late effects of therapy.

Follow-up (Table 6) includes a physical examination, chest radiography or alternatively low-dose chest CT (HR-CT), conventional radiography and MRI of the primary tumor region, and late follow-up diagnostic tests. Imaging intervals are every 3 months for the first 2 years, semiannually for the 3rd to 5th years, and then annually until 10 years after primary diagnosis. If recurrence is suspected, FDG-PET/CT or FDG-PET MRI may be helpful in individual cases.

**Table 6: Follow-up schedule**

Modality	Time/interval (months)		
	0-24	24-60	>5 years
	Every 3 months	Every 6 months	1 x yearly
X-ray thorax or CT thorax	x	x	x
X-ray primary tumor region	x	x	x
MRI primary tumor region	x	x	x

## 9 References

1. Bielack SS, Machatschek JN, Flege S, Jürgens H. Delaying surgery with chemotherapy for osteosarcoma of the extremities. *Expert Opin Pharmacother* 2004;5:1243-1256. DOI:10.1517/14656566.5.6.1243.
2. Bernthal NM, Federman N, Eilber FR et al. Long-term results (>25 years) of a randomized, prospective clinical trial evaluating chemotherapy in patients with high-grade, operable osteosarcoma. *Cancer* 2012;118:5888-5893. DOI:10.1002/cncr.27651.

3. Anninga JK, Gelderblom H, Fiocco M et al. Chemotherapeutic adjuvant treatment for osteosarcoma: where do we stand? *Eur J Cancer* 2011;47:2431-2445. DOI:10.1016/j.ejca.2011.05.030
4. Ozaki T, Flege S, Liljenqvist U et al. Osteosarcoma of the spine: experience of the Cooperative Osteosarcoma Study Group. *Cancer* 2002;94:1069-1077. PMID:11920477.
5. Bielack S, Jürgens H, Jundt G et al. Osteosarcoma: the COSS experience. *Cancer Treat Res* 2009;152:289-308. DOI:10.1007/978-1-4419-0284-9\_15.
6. Bielack SS, Kempf-Bielack B, Delling G et al. Prognostic factors in high-grade osteosarcoma of the extremities or trunk: an analysis of 1,702 patients treated on neoadjuvant cooperative osteosarcoma study group protocols. *J Clin Oncol* 2002;20:776-790. DOI:10.1200/JCO.2002.20.3.776.
7. Strauss SJ, Frezza AM, Abecassis N et al. Bone sarcomas: ESMO-EURACAN-GENTURIS-ERN PaedCan Clinical Practice Guideline for diagnosis, treatment and follow-up. *Ann Oncol* 2021;32:1520-1536. DOI:10.1016/j.annonc.2021.08.1995.
8. Smida J, Baumhoer D, Rosemann M et al. Genomic alterations and allelic imbalances are strong prognostic predictors in osteosarcoma. *Clin Cancer Res* 2010;16:4256-4267. DOI:10.1158/1078-0432.CCR-10-0284.
9. Kovac M, Blattmann C, Ribi S et al. Exome sequencing of osteosarcoma reveals mutation signatures reminiscent of BRCA deficiency. *Nat Commun* 2015;6:8940. DOI:10.1038/ncomms9940.
10. Smeland S, Bielack SS, Whelan J et al. Survival and prognosis with osteosarcoma: outcomes in more than 2000 patients in the EURAMOS-1 (European and American Osteosarcoma Study) cohort. *Eur J Cancer* 2019;109:36-50. DOI:10.1016/j.ejca.2018.11.027.
11. Kaste SC, Pratt CB, Cain AM, Jones-Wallace DJ, Rao BN. Metastases detected at the time of diagnosis of primary pediatric extremity osteosarcoma: imaging features. *Cancer* 1999;86:1602-1608. DOI:10.1002/(sici)1097-0142(19991015)86:8<1602::aid-cncr31>3.0.co;2-r
12. Ruengwanichayakun P, Gambarotti M, Frisoni T et al. Parosteal osteosarcoma: a monocentric retrospective analysis of 195 patients. *Hum Pathol* 2019;91:11-18. DOI:10.1016/j.humpath.2019.05.009
13. Berner K, Johannesen TB, Bruland ØS. Clinical epidemiology of low-grade and dedifferentiated osteosarcoma in Norway during 1975 and 2009. *Sarcoma* 2015;2015:917679. DOI:10.1155/2015/917679.
14. Grimer RJ, Bielack S, Flege S et al. Periosteal osteosarcoma - a European review of outcome. *European journal of cancer* 2005;41:2806-2811. DOI:10.1016/j.ejca.2005.04.052.
15. Cesari M, Alberghini M, Vanel D et al. Periosteal osteosarcoma: a single-institution experience. *Cancer* 2011;117:1731-1735. DOI:10.1002/cncr.25718.
16. Goorin AM, Schwartzentruber DJ, Devidas M et al. Presurgical chemotherapy compared with immediate surgery and adjuvant chemotherapy for nonmetastatic osteosarcoma: Pediatric Oncology Group Study POG-8651. *J Clin Oncol* 2003;21:1574-1580. DOI:10.1200/JCO.2003.08.165.
17. Grohar PJ, Janeway KA, Mase LD, Schiffman JD. Advances in the treatment of pediatric bone sarcomas. *Am Soc Clin Oncol Educ Book* 2017;37:725-735. DOI:10.1200/EDBK\_175378.
18. Bielack S, Cable MG, Gorlick R et al. Osteosarcoma - approach to therapy. In: Arndt CAS, ed. *Sarcomas of Bone and Soft Tissues in Children and Adolescents*. Cham: Springer International Publishing; 2021:91-109. DOI:10.1007/978-3-030-51160-9\_8.

19. Bacci G, Bertoni F, Longhi A et al. Neoadjuvant chemotherapy for high-grade central osteosarcoma of the extremity. Histologic response to preoperative chemotherapy correlates with histologic subtype of the tumor. *Cancer* 2003;97:3068-3075. DOI:10.1002/cncr.11456.
20. Hauben EI, Weeden S, Pringle J, Van Marck EA, Hogendoorn PC. Does the histological subtype of high-grade central osteosarcoma influence the response to treatment with chemotherapy and does it affect overall survival? A study on 570 patients of two consecutive trials of the European Osteosarcoma Intergroup. *Eur J Cancer* 2002;38:1218-1225. DOI:10.1016/s0959-8049(02)00037-0.
21. Bacci G, Longhi A, Versari M, Mercuri M, Briccoli A, Picci P. Prognostic factors for osteosarcoma of the extremity treated with neoadjuvant chemotherapy: 15-year experience in 789 patients treated at a single institution. *Cancer* 2006;106:1154-1161. DOI:10.1002/cncr.21724.
22. Imran H, Enders F, Krailo M et al. Effect of time to resumption of chemotherapy after definitive surgery on prognosis for non-metastatic osteosarcoma. *J Bone Joint Surg Am* 2009;91:604-612. DOI:10.2106/JBJS.H.00449.
23. Mialou V, Philip T, Kalifa C et al. Metastatic osteosarcoma at diagnosis: prognostic factors and long-term outcome - the French pediatric experience. *Cancer* 2005;104:1100-1109. DOI:10.1002/cncr.21263.
24. Kager L, Zoubek A, Pötschger U et al. Primary metastatic osteosarcoma: presentation and outcome of patients treated on neoadjuvant Cooperative Osteosarcoma Study Group protocols. *J Clin Oncol* 2003 May;21:2011-2018. DOI:10.1200/JCO.2003.08.132.
25. Aljubran AH, Griffin A, Pintilie M, Blackstein M. Osteosarcoma in adolescents and adults: survival analysis with and without lung metastases. *Ann Oncol* 2009;20:1136-1141. DOI:10.1093/annonc/mdn731 Erratum in: *Ann Oncol* 2021;32:424. PMID:19153114.
26. Bielack SS, Smeland S, Whelan JS et al. methotrexate, doxorubicin, and cisplatin (MAP) plus maintenance pegylated interferon alfa-2b versus MAP alone in patients with resectable high-grade osteosarcoma and good histologic response to preoperative MAP: first results of the EURAMOS-1 good response randomized controlled trial. *J Clin Oncol* 2015;33:2279-2287. doi: 10.1200/JCO.2014.60.0734. Erratum in: *J Clin Oncol* 2016;34:4059. PMID:26033801.
27. Marina NM, Smeland S, Bielack SS et al. Comparison of MAPIE versus MAP in patients with a poor response to preoperative chemotherapy for newly diagnosed high-grade osteosarcoma (EURAMOS-1): an open-label, international, randomised controlled trial. *Lancet Oncol* 2016;17:1396-1408. DOI:10.1016/S1470-2045(16)30214-5.
28. Meyers PA, Schwartz CL, Krailo MD et al. Osteosarcoma: the addition of muramyl tripeptide to chemotherapy improves overall survival - a report from the Children's Oncology Group. *J Clin Oncol* 2008;26:633-638. DOI:10.1200/JCO.2008.14.0095.
29. Bielack SS, Marina N, Ferrari S et al. Osteosarcoma: the same old drugs or more? *J Clin Oncol* 2008;26:3102-3103. DOI:10.1200/JCO.2008.17.1108.
30. Ferrari S, Bielack SS, Smeland S et al. EURO-B.O.S.S.: A European study on chemotherapy in bone-sarcoma patients aged over 40: outcome in primary high-grade osteosarcoma. *Tumori* 2018;104:30-36. DOI:10.5301/tj.5000696.
31. Jasнау S, Meyer U, Potratz J et al. Craniofacial osteosarcoma Experience of the cooperative German-Austrian-Swiss osteosarcoma study group. *Oral Oncol* 2008;44:286-294. DOI:10.1016/j.oraloncology.2007.03.001.
32. Thariat J, Julieron M, Bouchet A et al. Osteosarcomas of the mandible: are they different from other tumor sites? *Crit Rev Oncol Hematol* 2012;82:280-295. DOI:10.1016/j.critrevonc.2011.07.001.

33. Baumhoer D, Brunner P, Eppenberger-Castori S, Smida J, Nathrath M, Jundt G. Osteosarcomas of the jaws differ from their peripheral counterparts and require a distinct treatment approach. Experiences from the DOESAK Registry. *Oral Oncol* 2014;50:147-153. DOI:10.1016/j.oraloncology.2013.10.017.
34. Frezza AM, Beale T, Bomanji J et al. Is [F-18]-fluorodeoxy-D-glucose positron emission tomography of value in the management of patients with craniofacial bone sarcomas undergoing neo-adjuvant treatment? *BMC Cancer* 2014;14:23. DOI:10.1186/1471-2407-14-23.
35. Andreou D, Bielack SS, Carrle D et al. The influence of tumor- and treatment-related factors on the development of local recurrence in osteosarcoma after adequate surgery. An analysis of 1355 patients treated on neoadjuvant Cooperative Osteosarcoma Study Group protocols. *Ann Oncol* 2011;22:1228-1235. DOI:10.1093/annonc/mdq589.
36. Harges J, Guder W, Dudda M, Nottrott M, Podleska LE, Streitburger A. Aktuelle Ergebnisse der Tumorendoprothetik bei Jugendlichen und Erwachsenen [Current results of tumor endoprosthetics in adolescents and adults]. *Orthopade* 2019;48:744-751. English. DOI:10.1007/s00132-019-03788-5
37. Grimsrud C, Killen C, Murphy M, Wang H, McGarry S. Long-term outcomes of rotation-plasty patients in the treatment of lower extremity sarcomas with cost analysis. *J Clin Orthop Trauma* 2020;11(Suppl 1):S149-S152. DOI:10.1016/j.jcot.2019.06.003
38. Ferrari S, Briccoli A, Mercuri M et al. Postrelapse survival in osteosarcoma of the extremities: prognostic factors for long-term survival. *J Clin Oncol* 2003;21:710-715. DOI:10.1200/JCO.2003.03.141.
39. Chou AJ, Kleinerman ES, Krailo MD et al. Addition of muramyl tripeptide to chemotherapy for patients with newly diagnosed metastatic osteosarcoma: a report from the Children's Oncology Group. *Cancer* 2009;115:5339-5348. DOI:10.1002/cncr.24566.
40. Kempf-Bielack B, Bielack SS, Jürgens H et al. Osteosarcoma relapse after combined modality therapy: an analysis of unselected patients in the Cooperative Osteosarcoma Study Group (COSS). *J Clin Oncol* 2005;23:559-568. DOI:10.1200/JCO.2005.04.063.
41. de Baere T, Tselikas L, Gravel G et al. Interventional radiology: role in the treatment of sarcomas. *Eur J Cancer* 2018;94:148-155. DOI:10.1016/j.ejca.2018.02.017.
42. Palmerini E, Torricelli E, Cascinu S et al. Is there a role for chemotherapy after local relapse in high-grade osteosarcoma? *Pediatr Blood Cancer* 2019;66:e27792. DOI:10.1002/pbc.27792
43. Gazouli I, Kyriazoglou A, Kotsantis I et al. Systematic review of recurrent osteosarcoma systemic therapy. *Cancers (Basel)* 2021;13:1757. DOI:10.3390/cancers13081757.
44. Palmerini E, Jones RL, Marchesi E et al. Gemcitabine and docetaxel in relapsed and unresectable high-grade osteosarcoma and spindle cell sarcoma of bone. *BMC Cancer* 2016;16:280. DOI:10.1186/s12885-016-2312-3.
45. Navid F, Willert JR, McCarville MB et al. Combination of gemcitabine and docetaxel in the treatment of children and young adults with refractory bone sarcoma. *Cancer* 2008;113:419-425. DOI:10.1002/cncr.23586.
46. Saylor RL, 3rd, Stine KC, Sullivan J et al. Cyclophosphamide plus topotecan in children with recurrent or refractory solid tumors: a Pediatric Oncology Group phase II study. *J Clin Oncol* 2001;19:3463-3469. DOI:10.1200/JCO.2001.19.15.3463.
47. Daw NC, Chou AJ, Jaffe N et al. Recurrent osteosarcoma with a single pulmonary metastasis: a multi-institutional review. *Br J Cancer* 2015;112:278-282. DOI:10.1038/bjc.2014.585.

48. Grignani G, Palmerini E, Ferraresi V et al. Sorafenib and everolimus for patients with unresectable high-grade osteosarcoma progressing after standard treatment: a non-randomised phase 2 clinical trial. *Lancet Oncol* 2015;16:98-107. DOI:10.1016/S1470-2045(14)71136-2.
49. Grignani G, Palmerini E, Dileo P et al. A phase II trial of sorafenib in relapsed and unresectable high-grade osteosarcoma after failure of standard multimodal therapy: an Italian Sarcoma Group study. *Ann Oncol* 2012;23:508-516. DOI:10.1093/annonc/mdr151.
50. Martin-Broto J, Redondo A, Valverde C et al. Gemcitabine plus sirolimus for relapsed and progressing osteosarcoma patients after standard chemotherapy: a multicenter, single-arm phase II trial of Spanish Group for Research on Sarcoma (GEIS). *Ann Oncol* 2017;28:2994-2999. DOI:10.1093/annonc/mdx536.
51. Duffaud F, Mir O, Boudou-Rouquette P et al. Efficacy and safety of regorafenib in adult patients with metastatic osteosarcoma: a non-comparative, randomised, double-blind, placebo-controlled, phase 2 study. *Lancet Oncol* 2019;20:120-133. DOI:10.1016/S1470-2045(18)30742-3.
52. Davis LE, Bolejack V, Ryan CW et al. Randomized double-blind phase II study of regorafenib in patients with metastatic osteosarcoma. *J Clin Oncol* 2019;37:1424-1431. DOI:10.1200/JCO.18.02374.
53. Italiano A, Mir O, Mathoulin-Pelissier S et al. Cabozantinib in patients with advanced Ewing sarcoma or osteosarcoma (CABONE): a multicentre, single-arm, phase 2 trial. *Lancet Oncol* 2020;21:446-455. DOI:10.1016/S1470-2045(19)30825-3.
54. Marabelle A, Fakih M, Lopez J et al. Association of tumour mutational burden with outcomes in patients with advanced solid tumours treated with pembrolizumab: prospective biomarker analysis of the multicohort, open-label, phase 2 KEYNOTE-158 study. *Lancet Oncol* 2020;21:1353-1365. DOI:10.1016/S1470-2045(20)30445-9.
55. Marabelle A, Le DT, Ascierto PA et al. Efficacy of pembrolizumab in patients with noncolorectal high microsatellite instability/mismatch repair-deficient cancer: results from the phase II KEYNOTE-158 study. *J Clin Oncol* 2020;38:1-10. DOI:10.1200/JCO.19.02105.
56. Schenker M, Burotto M, Richardet M et al. Abstract CT022: CheckMate 848: A randomized, open-label, phase 2 study of nivolumab in combination with ipilimumab or nivolumab monotherapy in patients with advanced or metastatic solid tumors of high tumor mutational burden. *Cancer research* 2022;82(12\_supplement):CT022-CT022. DOI:10.1158/1538-7445.AM2022-CT022

## 15 Authors' Affiliations

### **PD Dr. Dimosthenis Andreou**

Medizinische Universität Graz  
Klinik für Orthopädie und Traumatologie  
Auenbruggerplatz 5/6  
A-8036 Graz  
[dimosthenis.andreou@gmail.com](mailto:dimosthenis.andreou@gmail.com)

### **Prof. Dr. Sebastian Bauer**

Universitätsklinikum Essen  
Innere Klinik (Tumorforschung)  
Westdeutsches Tumorzentrum  
Hufelandstr. 55  
45122 Essen  
[sebastian.bauer@uk-essen.de](mailto:sebastian.bauer@uk-essen.de)

**Prof. Dr. Stefan Bielack**

Klinikum Stuttgart  
Pädiatrie 5 Onkologie, Hämatologie und Immunologie  
Kriegsbergstr. 60  
70174 Stuttgart  
[s.bielack@klinikum-stuttgart.de](mailto:s.bielack@klinikum-stuttgart.de)

**Dr. med. Matthias Grube**

Universitätsklinikum Regensburg  
Innere Medizin III  
Franz-Josef-Strauß-Allee 11  
93042 Regensburg  
[matthias.grube@ukr.de](mailto:matthias.grube@ukr.de)

**Prof. Dr. Wolfgang Hartmann**

Universitätsklinikum Münster  
Gerhard-Domagk-Institut für Pathologie  
Domagkstr. 17  
48149 Münster  
[wolfgang.hartmann@ukmuenster.de](mailto:wolfgang.hartmann@ukmuenster.de)

**Dr. Stefanie Hecker-Nolting**

Klinikum Stuttgart  
Pädiatrie 5 Onkologie, Hämatologie und Immunologie  
Kriegsbergstr. 60  
70174 Stuttgart  
[s.hecker-nolting@klinikum-stuttgart.de](mailto:s.hecker-nolting@klinikum-stuttgart.de)

**PD Dr. med. Attila Kollár**

Spitalzentrum Biel  
Vogelsang 84  
CH-2501 Biel  
[attila.kollar@szb-chb.ch](mailto:attila.kollar@szb-chb.ch)

**Dr. med. Klaus Kraywinkel**

Zentrum für Krebsregisterdaten  
Robert Koch-Institut  
General-Pape-Straße 62-66  
12101 Berlin  
[k.kraywinkel@rki.de](mailto:k.kraywinkel@rki.de)

**Prof. Dr. Lars H. Lindner**

Ludwig-Maximilians-Universität  
Campus Großhadern  
Medizinische Klinik und Poliklinik III  
Marchioninistr.15  
81377 München  
[Lars.Lindner@med.uni-muenchen.de](mailto:Lars.Lindner@med.uni-muenchen.de)

**PD Dr. Joanna Szkandera**

Medizinische Universität Graz  
Klinische Abteilung für Onkologie  
Auenbruggerplatz 15  
A-8036 Graz  
[joanna.szkandera@medunigraz.at](mailto:joanna.szkandera@medunigraz.at)

**Prof. Dr. Beate Timmermann**

Universitätsklinikum Essen  
Westdeutsches Protonentherapiezentrum  
Hufelandstr. 55  
45122 Essen  
[beate.timmermann@uk-essen.de](mailto:beate.timmermann@uk-essen.de)

**Dr. med. Per Ulf Tunn**

Helios-Klinikum Berlin-Buch  
Klinik für Tumororthopädie  
Schwanebecker Chaussee 50  
13125 Berlin  
[per-ulf.tunn@helios-kliniken.de](mailto:per-ulf.tunn@helios-kliniken.de)

**Prof. Dr. Klaus Wörtler**

Technische Universität München  
Klinikum rechts der Isar  
Diagnostische und Interventionelle Radiologie  
Ismaninger Str. 22  
81675 München  
[klaus.woertler@tum.de](mailto:klaus.woertler@tum.de)

## **16 Disclosures**

according to the [rules of DGHO, OeGHO, SGH+SSH, SGMO](#)

Author	Employer <sup>1</sup>	Consulting / Expert opinion <sup>2</sup>	Shares / Funds <sup>3</sup>	Patent / Copyright / License <sup>4</sup>	Fees <sup>5</sup>	Funding of scientific research <sup>6</sup>	Other financial relations <sup>7</sup>	Personal relationship with authorized representatives <sup>8</sup>
Andreou, Dimosthenis	Aktuell: Medizinische Universität Graz Davor: Helios Klinikum Bad Saarow	No	No	No	Yes Honorare für Vortragstätigkeiten: PharmaMar	No	No	No
Bauer, Sebastian	Universitätsklinikum Essen	No	No	No	No	No	No	No
Bielack, Stefan	Klinikum Stuttgart Pädiatrie 5 Onkologie, Hämatologie und Immunologie	Yes MAP biopharma, Y-mabs, ELSAI, Boehringer-Ingelheim, Hoffmann-La Roche	No	No	No	No	No	No
Grube, Matthias	Medizinische Klinik und Poliklinik III Universitätsklinikum Regensburg 93042 Regensburg	Yes Berater/Advisory Board der Firmen: - Janssen - Sanofi - Bayer	No	No	Yes Firma AURIKAMED	No	Yes Pharmamar	No
Hartmann, Wolfgang	Universitätsklinikum Münster	No	No	No	No	No	No	No
Hecker-Nolting, Stefanie	Conflict of interest declarations pending							
Kollár, Attila	Inselspital, Universitätsspital Bern Universitätsklinik für Medizinische Onkologie	No	No	No	Yes Lilly, Bayer, PharmaMar, Amgen	No	Yes PharmaMar, Vifor	No
Kraywinkel, Klaus	Robert Koch-Institut	No	No	No	No	No	No	No
Lindner, Lars H.	LMU Klinikum, München	No	No	No	No	No	No	No
Szkandera, Joanna	Medizinische Universität Graz	Yes Advisory Board für PharmaMar, Lilly, Bayer	No	No	Yes Vorträge für PharmaMar, Roche, Lilly	Yes Forschungsförderung von PharmaMar, Roche, Eisai	Yes Reisekostenerstattung für Kongresse von PharmaMar, Roche, Lilly	No
Timmermann, Beate	Conflict of interest declarations pending							

Author	Employer <sup>1</sup>	Consulting / Expert opinion <sup>2</sup>	Shares / Funds <sup>3</sup>	Patent / Copyright / License <sup>4</sup>	Fees <sup>5</sup>	Funding of scientific research <sup>6</sup>	Other financial relations <sup>7</sup>	Personal relationship with authorized representatives <sup>8</sup>
Tunn, Per Ulf	Helios Klinikum Berlin Buch Klinik für Tumorthopädie Schwanebecker Chaussee 50 13125 Berlin	No	No	No	No	No	No	No
Wörtler, Klaus	Klinikum rechts der Isar der TU München	No	No	No	No	No	No	No

*Legend:*

<sup>1</sup> - Current employer, relevant previous employers in the last 3 years (institution/location).

<sup>2</sup> - Activity as a consultant or expert or paid participation in a scientific advisory board of a company in the health care industry (e.g., pharmaceutical industry, medical device industry), a commercially oriented contract research organization, or an insurance company.

<sup>3</sup> - Ownership of business shares, stocks, funds with participation of companies of the health care industry.

<sup>4</sup> - Relates to drugs and medical devices.

<sup>5</sup> - Honoraria for lecturing and training activities or paid authors or co-authorships on behalf of a company in the health care industry, a commercially oriented contracting institute or an insurance company.

<sup>6</sup> - Financial support (third-party funds) for research projects or direct financing of employees of the institution by a company in the health care industry, a commercially oriented contract institute or an insurance company.

<sup>7</sup> - Other financial relationships, e.g., gifts, travel reimbursements, or other payments in excess of 100 euros outside of research projects, if paid by an entity that has an investment in, license to, or other commercial interest in the subject matter of the investigation.

<sup>8</sup> - Personal relationship with an authorized representative(s) of a healthcare company.