

# Hereditary Spherocytosis (Spherocytic Anemia)

Recommendations from the society for diagnosis and therapy of haematological and oncological diseases

## **Publisher**

DGHO Deutsche Gesellschaft für Hämatologie und  
Medizinische Onkologie e.V.  
Bauhofstr. 12  
D-10117 Berlin

Executive chairman: Prof. Dr. med. Andreas Hochhaus

Phone: +49 (0)30 27 87 60 89 - 0

[info@dgho.de](mailto:info@dgho.de)

[www.dgho.de](http://www.dgho.de)

## **Contact person**

Prof. Dr. med. Bernhard Wörmann  
Medical superintendent

## **Source**

[www.onkopedia-guidelines.info](http://www.onkopedia-guidelines.info)

The information of the DGHO Onkopedia Web Site is not intended or implied to be a substitute for professional medical advice or medical care. The advice of a medical professional should always be sought prior to commencing any form of medical treatment. To this end, all component information contained within the web site is done so for solely educational purposes. DGHO Deutsche Gesellschaft für Hämatologie und Onkologie and all of its staff, agents and members disclaim any and all warranties and representations with regards to the information contained on the DGHO Web Site. This includes any implied warranties and conditions that may be derived from the aforementioned web site information.

# Table of contents

<b>1 Summary</b> .....	<b>2</b>
<b>2 Basics</b> .....	<b>2</b>
2.1 Definition and basic information .....	2
2.2 Epidemiology .....	2
2.3 Pathogenesis.....	2
<b>3 Prevention and screening</b> .....	<b>3</b>
<b>4 Clinical picture</b> .....	<b>3</b>
4.1 Symptoms.....	3
4.2 Asymptomatic persons with abnormal laboratory parameters .....	5
4.3 MCHC as an indicator of erythrocyte membrane disease .....	5
<b>5 Diagnosis</b> .....	<b>6</b>
5.1 Diagnostics for suspected hereditary spherocytosis.....	6
5.1.1 Acidified Glycerol Lysis Time (AGLT).....	7
5.1.2 Flow cytometry (eosin-5-maleimide test) .....	7
5.1.3 Ektacytometry .....	7
5.1.4 Membrane Analysis.....	7
5.1.5 Genetic Analysis .....	7
5.2 Differential diagnosis .....	8
5.2.1 Hereditary.....	8
5.2.2 Acquired.....	9
<b>6 Therapy</b> .....	<b>10</b>
6.1 Splenectomy .....	10
<b>8 Follow-up</b> .....	<b>10</b>
8.1 Controls in asymptomatic patients .....	10
8.2 Genetic counseling .....	11
<b>9 References</b> .....	<b>11</b>
<b>15 Authors' Affiliations</b> .....	<b>13</b>
<b>16 Disclosures</b> .....	<b>13</b>

# Hereditary Spherocytosis (Spherocytic Anemia)

**Date of document:** July 2022

## **Compliance rules:**

- [Guideline](#)
- [Conflict of interests](#)

**Authors:** Bernhard Wörmann, Stefan Eber, Jeroen Goede, Anette Hoferer, Hubert Schrezenmeier, Christian Sillaber

**Previous authors:** Gerhard Ehninger, Winfried Gassmann, Hermann Heimpel

## **1 Summary**

Hereditary spherocytosis (HS) belongs to the group of hemolytic anemias. It is caused by different mutations in the genes for  $\alpha$ -spectrin,  $\beta$ -spectrin, ankyrin-1, band 3 or protein 4.2. The majority of mutations are inherited in an autosomal dominant manner. They lead to a loss of cohesion between the membrane skeleton and the lipid layer. Due to the altered erythrocyte deformability, the erythrocytes are increasingly degraded in the spleen.

The clinical manifestation is highly variable and ranges from asymptomatic courses to clinically relevant hemolysis symptoms. There is no causal therapy. In many patients, an observational approach is indicated. The most effective therapy is splenectomy. In symptomatic patients, partial or total splenectomy is recommended.

## **2 Basics**

### **2.1 Definition and basic information**

Hereditary spherocytosis (HS) is a heterogeneous group of disorders of erythrocytes. The common denominator are structural membrane defects that lead to changes in erythrocyte deformability. The very variable clinical expression is due to the different mutations of the membrane protein genes, the different functional effects and the respective mode of inheritance.

The clinical picture was first described in the second half of the 19th century. In 1900, Oskar Minkowski published his observations on familial clustering [1]. Hereditary spherocytosis belongs to the congenital hemolytic anemias, the name is due to the microscopic aspect of spherical cells in the blood smear.

### **2.2 Epidemiology**

The prevalence is estimated to be about 1:2,500 - 5,000 in Germany, exact numbers are not available [2]. Hereditary spherocytosis is by far the most common congenital hemolytic anemia in individuals with a northern or central European background, but belongs to the rare diseases [3].

### **2.3 Pathogenesis**

Common causes of the various forms of hereditary spherocytosis are defects in the proteins of the erythrocyte membrane. As a result, the cohesion with the lipid bilayer is disturbed, and the surface area and deformability of the erythrocytes are progressively reduced. One of the conse-

quences is accelerated degradation of the dysfunctional erythrocytes in the spleen. In hereditary spherocytosis, the genes for the membrane proteins ankyrin, band 3, and spectrin are most commonly affected [4, 5]. Less common are alterations in the genes of protein 4.2, the Rh complex, and cases in which the protein defect is not definable. In about 75% of affected individuals, the disease is inherited in an autosomal dominant manner. In the remaining patients, recessive inheritance or new mutations are present. A classification based on the molecular basis is shown in Table 1 [4, 5, 6, 7].

**Table 1: Molecular classification of hereditary spherocytosis.**

Protein	Gene	Frequency <sup>1</sup>	Inheritance <sup>2</sup>	Progress form <sup>3</sup>	OMIM <sup>4</sup>
Ankyrin-1	<i>ANK1</i>	40 - 65%	autosomal dominant	mostly moderate; rarely light or heavy	#182900
α Spectrin,	<i>SPTA1</i>	< 5%	autosomal recessive	mostly light, rarely severe with biallelic mutations	#270970
β Spectrin,	<i>SPTB</i>	15 - 30%	autosomal dominant	easy to medium	#182870
Band 3	<i>SLC4A1</i>	20 - 35%	autosomal dominant	easy to moderate; very rarely severe recessive form	#109270
Protein 4.2	<i>EPB42</i>	< 5%	autosomal recessive	easy to medium	#612690

Legend:

<sup>1</sup> Frequency - relative frequency in Central Europe;

<sup>2</sup> related to monoallelic forms;

<sup>3</sup> progression form - see Table 2;

<sup>4</sup> OMIM - Online Mendelian Inheritance in Man [8].

The spectrum of mutations in affected genes is diverse: splicing, skipping, missense, nonsense, deletion, frameshift, polymorphisms [7, 8, 9, 10]. Many genetic aberrations are 'personal', i.e. specific to the affected family [11, 12, 13]. The clinical picture of HS within a family is often very similar.

### 3 Prevention and screening

Screening of asymptomatic newborns is not established. In children of patients with dominantly inherited HS, special attention should be paid to hemolysis symptoms [2, 14].

## 4 Clinical picture

### 4.1 Symptoms

The clinical spectrum of hereditary spherocytosis ranges from severe cases requiring transfusion already in childhood to asymptomatic patients with incidental diagnosis in old age on the occasion of a laboratory examination for other indications. The characteristic findings and typical complications are summarized in Tables 2 and 3.

**Table 2: Characteristic findings in hereditary spherocytosis**

Symptom	Note
Anemia	Coombs negative
Icterus	indirect bilirubin increased
Splenomegaly	variable level
Family history	positive in most patients (75%)

**Table 3: Typical complications of hereditary spherocytosis**

Symptom	Note
Cholelithias	due to chronic hemolysis
aplastic crisis	most frequently after first time infection with parvovirus B19
hemolytic crisis	after intercurrent infections
megaloblastic crisis	in patients with folic acid deficiency

Hemolytic crises occur repeatedly, especially in the context of intercurrent infections. The course is usually mild in young adults and blood transfusion is not required. The aplastic crisis is usually unique. It may result in a severe drop in hemoglobin concentration, requiring blood transfusion. Cardiovascular complications, extramedullary hematopoiesis, or secondary hemochromatosis are rare [5, 15]. Before making the diagnosis of secondary hemochromatosis in HS, primary causes such as HFE-associated hereditary hemochromatosis must be excluded. Hemolytic crises occur repeatedly, especially in the setting of intercurrent infections. The course is usually mild in young adults and blood transfusion is not required.

The chronically increased hemolysis can lead to extramedullary hematopoiesis with the clinical picture of intrathoracic, paravertebral tumors even in patients with a mild form of progression - who were not splenectomized - after decades of progression. Leg ulcers may occur in elderly patients.

A classification of hereditary spherocytosis based on clinical severity can be found in Table 4 [2, 11, 16].

**Table 4: Clinical classification of hereditary spherocytosis**

	Carrier	easy	moderately difficult	heavy	Very heavy
Patients (%) <sup>1</sup>		25 - 30	60 - 70	10	3 - 5
Hemoglobin (g/L)	normal	11 - 15	8 - 11	6 - 8	< 6
Reticulocytes (%)	1 - 4	< 6	≥ 6	> 10	> 10
Bilirubin (mg / dL)	< 1	1 - 2	≥ 2	≥ 2 - 3	≥ 3
Blood smear	normal, occasionally isolated spherocytes	isolated spherocytes	spherocytes detectable	spherocytes detectable	microspherocytes poikilocytosis
Transfusion requirements	no	0 - 1	0 - 2	≥ 3	regularly

Legend:

<sup>1</sup> Relative frequency (%);

<sup>2</sup> osmotic fragility;

## 4.2 Asymptomatic persons with abnormal laboratory parameters

A special group are carriers (adults without clinical symptoms and without a positive family history) in whom abnormal laboratory parameters were found by chance. Evidence of hereditary spherocytosis is summarized in [Table 5 \[16\]](#):

**Table 5: Laboratory evidence of hereditary spherocytosis**

Parameter	Comments
MCHC above the normal limit (35 or 36 g/dl)*.	a high specificity has the combination of MCHC above the normal limit and RDW >15%; In abortive mild forms, however, RDW values are rarely increased
Reticulocytes increased	may occur intermittently
Spherocytes	single
LDH increased Indirect bilirubin increased	rare
Haptoglobin decreased	occasionally also normal in asymptomatic individuals
Multiplication of hyperchromic, hyperdense erythrocytes	especially in moderate and severe spherocytosis
slight increase in osmotic fragility	in the particularly sensitive test methods (AGLT)
decreased binding of eosin-5-maleimide (band 3) to the erythrocyte membrane	EMA test pathological

*Legend:*

\* see [chapter 4.3](#) for a more detailed presentation of the parameter MCHC

The combination of several parameters confirms the suspected diagnosis of a predisposition for HS. If no spherocytes are detectable, no changes in indices are present, and reticulocytes are normal, hereditary spherocytosis cannot be ruled out, but it is unlikely that this individual will become symptomatic. Differentiation between a clinically asymptomatic predisposition and a mild form of spherocytosis can be difficult. Occasionally, mild forms may exacerbate in splenomegaly of other etiologies (e.g., lymphoma) or in viral infections (EBV, parvovirus).

## 4.3 MCHC as an indicator of erythrocyte membrane disease

The increased MCHC value (Mean Cellular Hemoglobin Concentration) has a special significance in the identification of spherocytosis patients. It measures the hemoglobin concentration in hemoglobin per 100 ml erythrocytes.

Increased MCHC levels may be due to medical, but also to technical reasons:

- hemoglobin level determined too high in case of plasma opacities of any kind
- erythrocyte count determined too low, e.g. in the case of coagulated blood
- high titre cold agglutinins
- hereditary membrane disorders of erythrocytes as in hereditary spherocytosis and variants such as xerocytosis
- hemoglobin CC abnormality
- homozygous sickle cell disease (occasionally)
- hemochromatosis patients with massive iron overload [15], also depending on genotype.

## 5 Diagnosis

### 5.1 Diagnostics for suspected hereditary spherocytosis

The diagnostic steps in adults are shown in [Tables 6](#) and [7](#) and as an algorithm in [Figure 1](#).

**Table 6: Basic diagnostics for suspected hereditary spherocytosis and evaluation of diagnostic criteria**

Parameter (mandatory)	Specification	Evaluation (as a diagnostic criterion)
<b>Family history</b>	<ul style="list-style-type: none"> <li>• autosomal dominant or recessive</li> </ul>	<ul style="list-style-type: none"> <li>• optional</li> </ul>
<b>Splenomegaly</b>	<ul style="list-style-type: none"> <li>• Physical examination</li> <li>• Ultrasound</li> </ul>	<ul style="list-style-type: none"> <li>• optional</li> </ul>
<b>Blood count automatically</b>	<ul style="list-style-type: none"> <li>• Anemia</li> <li>• MCHC<sup>1</sup> &gt; 35 g/dl</li> <li>• Anisocytosis (RDW<sup>2</sup>)</li> </ul>	<ul style="list-style-type: none"> <li>• optional</li> <li>• optional</li> <li>• optional</li> </ul>
<b>Blood count microscopic</b>	<ul style="list-style-type: none"> <li>• Spherocytes</li> <li>• Anisocytosis</li> </ul>	<ul style="list-style-type: none"> <li>• variable<sup>3, 4</sup></li> <li>• optional</li> </ul>
<b>increased hemolysis</b>	<ul style="list-style-type: none"> <li>• Reticulocytes increased or normal</li> <li>• low percentage of immature reticulocytes</li> <li>• Indirect bilirubin increased</li> <li>• LDH<sup>5</sup> increased</li> <li>• Haptoglobin not detectable</li> </ul>	<ul style="list-style-type: none"> <li>• at least 2 parameters mandatory</li> </ul>
<b>Coombs test</b>	<ul style="list-style-type: none"> <li>• negative</li> </ul>	<ul style="list-style-type: none"> <li>• mandatory</li> </ul>

Legend:

<sup>1</sup> MCHC - mean corpuscular hemoglobin concentration;

<sup>2</sup> RDW- size distribution of erythrocytes in automatic blood count;

<sup>3</sup> detectable only in perfect smears;

<sup>4</sup> microscopic picture may be uncharacteristic in adults; few or no spherocytes may be detectable in mild forms, while polychromasia and anisocytosis are almost always seen;

<sup>5</sup> LDH - lactate dehydrogenase;

**Table 7: Further diagnostics for suspected hereditary spherocytosis**

Parameter	Specification
Osmotic fragility	Acidified Glycerol Lysis Time (AGLT)
Flow cytometry	Eosin-5-maleimide binding
Ektacytometry	<ul style="list-style-type: none"> <li>• currently not available in Germany</li> <li>• available in Switzerland</li> </ul>
Membrane analysis	SDS PAGE
Gene analysis	Sequencing of candidate genes: linkage analysis

There is no single test that detects all forms of hereditary spherocytosis and reliably differentiates them from other forms of membrane-related hemolytic anemias [16, 17, 18, 19, 20, 21]. Therefore, examination with two test methods is recommended. Sensitivity of up to 100% can be achieved in the combination of AGLT and EMA test [18]. The examination of osmotic resistance with hypotonic salt solutions has a significantly lower sensitivity than AGLT and EMA test.



### **5.1.1 Acidified Glycerol Lysis Time (AGLT)**

The AGLT test measures the time to 50% hemolysis of a blood sample in a hypotonic saline/glycerol solution. Determination of hemolysis time with the Acidified Glycerol Lysis Time (AGLT) has high specificity, with sensitivity ranging from 80 to 95% [22]. The test must be performed within hours of blood collection or on samples sent by express mail (cooled shipping depending on the season)! It can also be positive in patients with acquired hemolytic anemia, chronic renal failure, or myelodysplastic syndrome [19].

### **5.1.2 Flow cytometry (eosin-5-maleimide test)**

The flow cytometric method (EMA test) was introduced in 2000 [23]. It is based on the decreased binding of the fluorescent dye eosin-5-maleimide in patients with hereditary spherocytosis compared to normal subjects. Sensitivity is 90 - 95%, specificity is 95 - 99%. Maximum delay between blood collection and test performance may not exceed 48 hrs. In hereditary pyropoikilocytosis the fluorescent dye is bound even less than in hereditary spherocytosis, in stomatocytosis the binding is increased [17]. The binding of eosin-5-maleimide may also be decreased in patients with congenital dyserythropoietic anemia type II (CDA type II).

### **5.1.3 Ektacytometry**

Precise characterization of osmotic fragility (and differentiation between spherocytosis and macrocytic stomatocytosis) is possible by means of osmotic gradient ektacytometry; however, this procedure is currently available in only a few laboratories and not in all countries. Since the examination can only be done in fresh blood samples taken at the site of examination, ektacytometry is reserved for a few exceptional cases in which the diagnosis cannot be clarified otherwise.

### **5.1.4 Membrane Analysis**

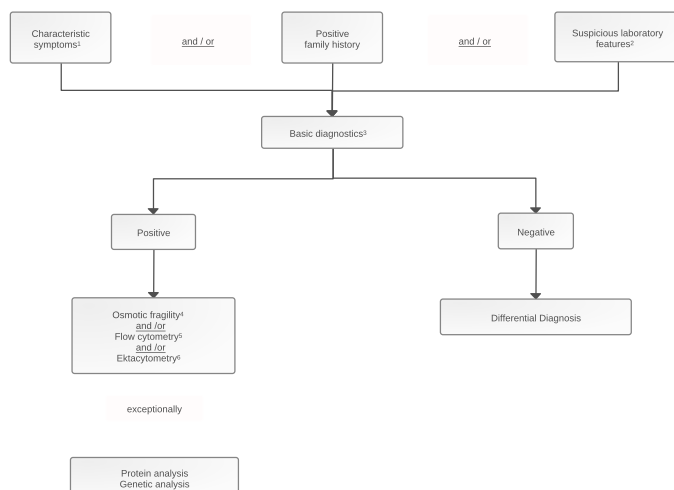
Biochemical analysis by gel electrophoresis can be used quantitatively to detect the decreased membrane proteins and qualitatively to identify the affected proteins. It rarely contributes to diagnostics.

### **5.1.5 Genetic Analysis**

Molecular genetic diagnostics identifies the patient- or family-specific genetic defect [9]. Due to the numerous target genes with the heterogeneity of possible mutations as well as the associated considerable costs, it is reserved for special cases in which a therapeutic consequence results from the diagnosis.

With all diagnostic methods, there are false positive and / or false negative results. Therefore, the diagnosis in individuals without a positive family history should generally not be based on one method, e.g., osmotic resistance only or EMA only or biochemical membrane diagnostics only. At least 2 different methods should be used. Also, future, diagnostic tests will have to be compared in their specificity and sensitivity with these laboratory methods.

**Figure 1: Diagnostic algorithm for suspected hereditary spherocytosis**



**Legend:**

- <sup>1</sup> characteristic symptoms - anemia, icterus, splenomegaly, hemolytic or aplastic crisis after viral infection;
- <sup>2</sup> abnormal laboratory findings - MCHC > 35 and RDW > 15 %; reticulocytes increased, hemolysis parameters positive;
- <sup>3</sup> Basic diagnostics - physical examination; CBC with microscopic differentiation of erythrocytes, reticulocytes, LDH, bilirubin, haptoglobin, direct Coombs test;
- <sup>4</sup> osmotic fragility - see chapter 5. 1. 1.
- <sup>5</sup> flow cytometric assay for dye binding, see chapter 5. 1. 2.
- <sup>6</sup> ektacytometry - see text chapter 5. 1. 3.

## 5.2 Differential diagnosis

The differential diagnosis in adult patients with hyperregenerative normochromic anemia and spherocytes includes:

### 5.2.1 Hereditary

*Hereditary elliptocytosis* [6, 7]: Findings of the basic diagnostics are largely identical to those of hereditary spherocytosis, but the osmotic fragility of erythrocytes is usually increased only in moderate to severe cases. The leading diagnostic procedure is the microscopic analysis of the blood smear with identification of elliptocytes. This also applies to *spherocytic elliptocytosis*, in which spherocytes are found in addition to elliptocytes.

*Hereditary pyropoikilocytosis*: Caused by homozygosity for spectrin abnormalities with a positive family history for hereditary elliptocytosis. Flow cytometric analysis (EMA test) shows clearly decreased binding of the dye as in HS. Crucial are the blood smear and a pronounced reduction of the MCV to values below 70 fl, in contrast to other membranopathies.

*Hereditary defects of erythrocyte membrane cation permeability*: differential diagnosis is summarized in Table 8 [6, 7, 24, 25].

**Table 8: Hereditary defects of the cation permeability of the erythrocyte membrane [modified from 24]**

	<b>Stomatocytosis with cellular hyperhydration</b>	<b>Cryohydrocytosis</b>	<b>Familial pseudohyperkalemia</b>	<b>Xerocytosis</b>
<b>Hemolysis</b>	<b>moderate to severe</b>	<b>mild to moderate</b>	<b>mild to normal</b>	<b>mild to moderate</b>
<b>MCV (80 - 100 fl)</b>	<b>110 - 150</b>	<b>90 - 105</b>	<b>82 - 104</b>	<b>84 - 122</b>
<b>MCHC (32 - 36 g/dL)</b>	<b>24 - 30</b>	<b>34 - 38</b>	<b>33 - 39</b>	<b>34 - 38</b>
<b>Erythrocytic Na<sup>+</sup>/K<sup>+</sup> (95-110 mmol/L Ery)</b>	<b>110 - 140</b>	<b>75 - 105</b>	<b>87-109</b>	<b>75-99</b>
<b>Osmotic fragility</b>	<b>Extremely increased</b>	<b>Normal to slightly increased</b>	<b>Slightly decreased</b>	<b>Decreased</b>
<b>Intrauterine ascites</b>	<b>no</b>	<b>no</b>	<b>no</b>	<b>Low to strong</b>
<b>Response to splenectomy</b>	<b>high risk of complications</b>	<b>bad</b>	<b>Splenectomy not required</b>	<b>bad</b>

Legend:

MCV - mean corpuscular volume; MCHC - mean hemoglobin concentration;

*Hereditary stomatocytosis:* The blood smear is crucial in this very rare clinical picture. Differentiation is important because splenectomy is often ineffective and associated with increased risk of thromboembolism. After storage of the blood sample at 4<sup>0</sup> C for 2 hours, serum potassium and MCV increase, MCHC normalizes.

*Hereditary xerocytosis (formerly also dehydrated hereditary stomatocytosis):* Largely unremarkable blood count, only rarely stomatocytes and echinocytes (especially in phase contrast microscopy). Osmotic fragility is slightly decreased. Patient history shows frequent intrauterine hydrops with ascites. Splenectomy is not effective and contraindicated due to increased risk of thromboembolism.

*Congenital dyserythropoietic anemia type II:* Although single spherocytes are also detectable in the smear, it shows marked poikilocytosis, almost always with basophilia. The reticulocyte count is often normal, but always not adequately increased in relation to the anemia. In case of doubt, detection of dyserythropoiesis in bone marrow aspirate is required for definite differentiation. The diagnosis is confirmed by the detection of the mutation of the *SEC23B* gene.

*Other forms of congenital hemolytic anemia:* Hereditary enzyme defects or structural defects of the hemoglobin genes also cause hemolytic anemia. Often, microscopic differential blood count can guide further diagnosis.

## 5.2.2 Acquired

- Autoimmune hemolytic anemia, especially the rare forms with a negative direct Coombs test
- Microangiopathic hemolytic anemia
- Hemolytic - uremic syndrome
- Hypophosphatemia
- (Delayed) hemolytic transfusion reaction
- Hemolysis of toxic or infectious origin

## 6 Therapy

There is no causal therapy for the genetic defect. The most effective symptomatic therapy is splenectomy. In symptomatic cholelithiasis, cholecystectomy is indicated [16, 26].

### 6.1 Splenectomy

Splenectomy often leads to reduction of anemia and regression of increased hemolysis parameters. The changes in the smear, on the other hand, usually become more obvious than before. The indication for splenectomy is usually given in childhood, but if possible not performed before school age [2]. However, it must also be considered in adulthood depending on the clinical findings [16, 26]. Splenectomy is also an option in adults with extramedullary hematopoiesis. Whether extramedullary hematopoiesis subsequently regresses is an open question.

If hemolysis persists after splenectomy, the diagnosis must be questioned again, a search must be made for an accessory spleen and this needs to be removed if necessary. The indication for splenectomy depends on the clinical severity, see Table 9 [2, 16].

**Table 9: Indications for splenectomy**

Severity	Recommendation
Mild	usually not required
Moderate	<ul style="list-style-type: none"><li>• In case of multiple hemolytic crises</li><li>• with &gt;2 transfusions in the last years</li><li>• with pronounced reduction in performance</li><li>• In symptomatic/painful splenomegaly with associated thrombocytopenia or leukocytopenia that affects the patient's quality of life.</li><li>• In severe jaundice leading to social problems; increased jaundice in the presence of concomitant Gilbert's syndrome.</li></ul>
Severe and very severe	all patients

The risk of splenectomy lies in the surgical procedure and the lifelong increased rate of severe infections, mainly due to pneumococci with a mortality of 0.1-0.4% [2, 27]. This risk is reduced by subtotal rather than total splenectomy [28, 29], thus the former procedure should be preferred. Most data on subtotal splenectomy are from children, not adults. In an analysis of the Splenectomy in Congenital Hemolytic Anemia Consortium Registry, the mean hemoglobin increase was higher after total splenectomy than after partial splenectomy (4.2 g/dl vs 2.4 g/dl,  $p < 0.001$ ) [30].

Laparoscopic splenectomy is an alternative for hereditary spherocytosis. It is safe [30, 31, 32]. However, to date, it is unclear whether laparoscopic partial resection is equivalent to open, subtotal splenectomy in terms of hematologic outcome and risk of recurrence.

Mild hemolysis with anemia may persist in patients with a severe course, especially with spectrin defects. In splenectomy, recommendations for vaccination and / or antibiotic prophylaxis must be followed.

## 8 Follow-up

### 8.1 Controls in asymptomatic patients

There are no studies on the effectiveness of regular controls. Blood count analyses should be performed on an as-needed basis, especially in cases of anemia symptoms in temporal relation

to infections. Because of the rare iron overload in moderate and severe forms, serum ferritin control is recommended at annual intervals. On the occasion of these controls, the vitamin B12 and folic acid levels should also be checked due to the increased need. Ultrasound of the bile ducts and spleen size is recommended at least every three years.

## 8.2 Genetic counseling

If the patient wishes to have children, family counseling with examination of the partner for erythrocytic membranopathy is recommended.

## 9 References

1. Minkowski O: Über eine hereditäre, unter dem Bilde eines chronischen Ikterus mit Urobilinurie, Splenomegalie und Nierensiderosis verlaufende Affection. Verh Dtsch Kongr Inn Med 18:316-319, 1990
2. S1-Leitlinie Hereditäre Sphärozytose 2016, 025-018. [https://www.awmf.org/uploads/tx\\_szleitlinien/025-018l-s1\\_hereditaere-sphaerozytose\\_2016-12](https://www.awmf.org/uploads/tx_szleitlinien/025-018l-s1_hereditaere-sphaerozytose_2016-12)
3. Orphanet, das Portal für seltene Erkrankungen. <https://www.orpha.net/>
4. Delaunay J: The molecular basis of hereditary red cell membrane disorders. Blood Reviews 21:1-20, 2007. DOI:10.1016/j.blre.2006.03.005
5. Perrotta S, Gallagher PG, Mohandas N: Hereditary spherocytosis. Lancet 372:1411-1426, 2008. DOI:10.1016/S0140-6736(08)61588-3
6. Mohandas N: Inherited hemolytic anemia: a possessive beginner's guide. Hematology Am Soc Hematol Educ Program 2018:377-381, 2018. DOI:10.1182/asheducation-2018.1.377
7. Iolascon A, Andolfo I, Russo R: Advances in understanding the pathogenesis of red cell membrane disorders. Br J Haematol 187:13-24, 2019. DOI:10.1111/bjh.16126
8. [www.ncbi.nlm.nih.gov/omim](http://www.ncbi.nlm.nih.gov/omim)
9. He BJ, Liao L, Deng ZF et al.: Molecular Genetic Mechanisms of Hereditary Spherocytosis: Current Perspectives. Acta Haematol 139:60-66, 2018. DOI:10.1159/000486229
10. Fattizzo B, Giannotta JA, Cecchi N et al.: Confounding factors in the diagnosis and clinical course of rare congenital hemolytic anemias. Orphanet J Rare Dis 16:415, 2021. DOI:10.1186/s13023-021-02036-4
11. Eber SW, Armbrust R, Schröter W. Variable clinical severity of hereditary spherocytosis: relation to erythrocytic spectrin concentration, osmotic fragility, and autohemolysis. J Pediatr 117:409-416, 1990. PMID:2391596
12. Cynober T, Mohandas N, Tchernia G: Red cell abnormalities in hereditary spherocytosis: relevance to diagnosis and understanding of the variable expression of clinical severity. J Lab Clin Med 128:259-269, 1996. PMID:8783633
13. Mariani M, Barcellini W, Vercellati C et al.: Clinical and hematologic features of 300 patients affected by hereditary spherocytosis grouped according to the type of the membrane protein defect. Haematologica 93:1310-1317, 2008. DOI:10.3324/haematol.12546
14. Michaels LA, Cohen AR, Zhao H, et al. Screening for hereditary spherocytosis by use of automated erythrocyte indexes. J Pediatr 130:957-960, 1997. DOI:10.1016/S0022-3476(97)70283-x
15. Barton JC, Bertoli LF, Rothenberg BE: Peripheral blood erythrocyte parameters in hemochromatosis: evidence for increased erythrocyte hemoglobin content. J Lab Clin Med 135: 96-104, 2000. PMID:16838333

16. Bolton-Maggs PHB, Langer JC, Iolascon A et al.: Guidelines for the diagnosis and management of hereditary spherocytosis – 2011 update. *Brit J Haematol* 156:37-49,2011. DOI:[10.1111/j.1365-2141.2011.08921.x](https://doi.org/10.1111/j.1365-2141.2011.08921.x)
17. Walensky LD, Mohandas N, Lux SE: Disorders of the blood cell membrane. In: Handin RI, Lux SE: Principles and practice of hematology. 2nd ed. Philadelphia: Lippincott Williams & Wilkins, 1726-17444, 2003.
18. Bianchi P, Fermo E, Vercellati C et al.: Diagnostic power of laboratory tests for hereditary spherocytosis: a comparison study on 150 patients grouped according to the molecular and clinical characteristics. *Haematologica* 97:516-523, 2012. DOI:[10.3324/haematol.2011.052845](https://doi.org/10.3324/haematol.2011.052845)
19. King MG, Garcon L, Hoyer JD et al. for the International Council for standardization in Haematology: ICSH guidelines for the laboratory diagnosis of nonimmune hereditary red cell membrane disorders
20. Farias MG. Advances in laboratory diagnosis of hereditary spherocytosis. *Clin Chem Lab Med* 55:944-948, 2017. DOI:[10.1515/cclm-2016-0738](https://doi.org/10.1515/cclm-2016-0738)
21. Ciepiela O: Old and new insights into the diagnosis of hereditary shphreocytosis. *Ann Transl Med* 6:339-348, 2018. DOI:[10.21037/atm.2018.07.35](https://doi.org/10.21037/atm.2018.07.35)
22. Eber SW, Pekrun A, Neufeldt A, Schröter W: Prevalence of increased osmotic fragility of erythrocytes in German blood donors: screening using a modified glycerol lysis test. *Ann Hematol* 64:88-92, 1992. PMID:[1554800](https://pubmed.ncbi.nlm.nih.gov/1554800/)
23. King MJ, Behrens J, Rogers C: Rapid flow cytometric test for the diagnosis of membrane cytoskeleton-associated haemolytic anaemia. *Brit J Haematol* 2000;111:924-933. DOI:[10.1111/j.1365-2141.2000.02416.x](https://doi.org/10.1111/j.1365-2141.2000.02416.x)
24. Eber S in Hämolytische Anämien. Hrsg.: J. Schubert, H. Schrezenmeier, Röth. UNI-MED 2009. ISBN: 9783837420890
25. Niss O, Chonat S, Dagaonkar N et al.: Genotype-phenotype correlations in hereditary elliptocytosis and hereditary pyropoikilocytosis, *Blood Cells Mol Dis* 61:4-9, 2016. DOI:[10.1016/j.bcmd.2016.07.003](https://doi.org/10.1016/j.bcmd.2016.07.003)
26. Marchetti M, Quaglini S, Barosi G: Prophylactic splenectomy and cholecystectomy in mild hereditary spherocytosis: analyzing the decision in different clinical scenarios. *J Intern Med* 244:217-226,1998. DOI:[10.1046/j.1365-2796.1998.00362.x](https://doi.org/10.1046/j.1365-2796.1998.00362.x)
27. Schilling RF: Risks and benefits of splenectomy versus no splenectomy in hereditary spherocytosis - a personal view. *Brit J Haematol* 145:728-723, 2009. DOI:[10.1111/j.1365-2141.2009.07694.x](https://doi.org/10.1111/j.1365-2141.2009.07694.x)
28. Bader-Meunier B, Gauthier F, Archambaud F et al.: Long-term evaluation of the beneficial effect of subtotal splenectomy for management of hereditary spherocytosis. *Blood* 97:399-403, 2001. DOI:[10.1182/blood.V97.2.399](https://doi.org/10.1182/blood.V97.2.399)
29. Stoehr GA, Sobh JN, Luecken J, et al.: Near-total splenectomy for hereditary spherocytosis: clinical prospects in relation to disease severity. *Br J Haematol* 132:791-793, 2006. DOI:[10.1111/j.1365-2141.2005.05956.x](https://doi.org/10.1111/j.1365-2141.2005.05956.x)
30. Tripodi SI, Shamberger RC, Heeney MM, Tubman VN: Clinical and laboratory outcomes following total or partial splenectomy in patients with hereditary spherocytosis. *Pediatr Hematol Oncol* 26:1-8, 2019. DOI:[10.1080/08880018.2019.1637983](https://doi.org/10.1080/08880018.2019.1637983)
31. Englum BR, Rothman J, Leonard S et al. for the Splenectomy in Congenial Hemolytic Anemia Consortium. Hematologic outcomes after total splenectomy and partial splenectomy for congenital hemolytic anemia. *J Pediatr. Surg* 51:122-127, 2016. DOI:[10.1016/j.jpedsurg.2015.10.028](https://doi.org/10.1016/j.jpedsurg.2015.10.028)

32. Guizetti L: Total versus partial splenectomy in pediatric hereditary spherocytosis: A systematic review and meta-analysis. *Pediatr. Blood Cancer* 63:1713-1722, 2016.  
[DOI:10.1002/psc.26106](https://doi.org/10.1002/psc.26106)

## 15 Authors' Affiliations

### **Prof. Dr. med. Bernhard Wörmann**

Amb. Gesundheitszentrum der Charité  
Campus Virchow-Klinikum  
Med. Klinik m.S. Hämatologie & Onkologie  
Augustenburger Platz 1  
13344 Berlin  
[bernhard.woermann@charite.de](mailto:bernhard.woermann@charite.de)

### **Prof. Dr. med. Stefan Eber**

Schwerpunktpraxis Pädiatrische  
Hämatologie/Onkologie und  
Kinderklinik der TU München  
Waldfriedhofstr. 738  
81377 München  
[praxis@kid-z.de](mailto:praxis@kid-z.de)

### **PD Dr.med. Jeroen Goede**

Medizinische Onkologie und Hämatologie  
Kantonsspital Winterthur  
Brauerstr. 15  
CH-8401 Winterthur  
[jeroen.goede@ksw.ch](mailto:jeroen.goede@ksw.ch)

### **Dr. Anette Hoferer**

Robert-Bosch-Krankenhaus  
Auerbachstr. 110  
70376 Stuttgart  
[anette.hoferer@rbk.de](mailto:anette.hoferer@rbk.de)

### **Prof. Dr. med. Hubert Schrezenmeier**

Universitätsklinikum Ulm  
Institut für klinische Transfusionsmedizin  
Helmholtzstr. 10  
89081 Ulm  
[h.schrezenmeier@blutspende.de](mailto:h.schrezenmeier@blutspende.de)

### **Univ.-Prof. Dr. Christian Sillaber**

Allgemeines Krankenhaus Wien  
Klinik für Innere Medizin I  
Klinische Abt. für Hämatologie  
und Hämostaseologie  
Währinger Gürtel 18-20  
A-1090 Wien  
[christian.sillaber@meduniwien.ac.at](mailto:christian.sillaber@meduniwien.ac.at)

## 16 Disclosures

according to the rules of the responsible Medical Societies.