

# Head and neck squamous cell carcinoma

Recommendations from the society for diagnosis and therapy of  
haematological and oncological diseases

---

## **Publisher**

DGHO Deutsche Gesellschaft für Hämatologie und  
Medizinische Onkologie e.V.  
Bauhofstr. 12  
D-10117 Berlin

Executive chairwoman: Prof. Dr. med. Claudia Baldus

Phone: +49 (0)30 27 87 60 89 - 0

[info@dgho.de](mailto:info@dgho.de)

[www.dgho.de](http://www.dgho.de)

## **Contact person**

Prof. Dr. med. Bernhard Wörmann  
Medical superintendent

## **Source**

[www.onkopedia-guidelines.info](http://www.onkopedia-guidelines.info)

The information of the DGHO Onkopedia Web Site is not intended or implied to be a substitute for professional medical advice or medical care. The advice of a medical professional should always be sought prior to commencing any form of medical treatment. To this end, all component information contained within the web site is done so for solely educational purposes. DGHO Deutsche Gesellschaft für Hämatologie und Onkologie and all of its staff, agents and members disclaim any and all warranties and representations with regards to the information contained on the DGHO Web Site. This includes any implied warranties and conditions that may be derived from the aforementioned web site information.

# Table of contents

<b>1 Summary</b>	<b>2</b>
<b>2 Basics</b>	<b>2</b>
2.1 Definition and basic information	2
2.2 Epidemiology (Figures 1-4)	2
2.3 Pathogenesis	2
2.4 Risk factors	2
<b>3 Prevention and early detection</b>	<b>2</b>
3.1 Prevention	2
3.2 Early detection	2
<b>4 Clinical image</b>	<b>2</b>
<b>5 Diagnosis</b>	<b>2</b>
5.1 Diagnostic procedures	2
5.2 Classification	2
5.2.1 Stages	2
5.2.2 Histology	2
5.2.2.1 WHO classification	2
5.2.2.2 TNM/UICC classification	2
5.2.2.3 Other parameters	2
<b>6 Therapy</b>	<b>2</b>
6.1 Treatment with curative intention	2
6.1.1 Multidisciplinary approach	2
6.1.2 Surgery	2
6.1.3 Radiotherapy	2
6.1.4 Adjuvant systemic therapy	2
6.1.5 Induction chemotherapy	2
6.2 Therapy with non-curative intention	2
6.2.1 First-line treatment	2
6.2.2 Second-line treatment	2
6.2.3 Systemic treatment agents (in alphabetical order)	2
6.2.3.1 -fluorouracil	2
6.2.3.2 Carboplatin	2
6.2.3.3 Cetuximab	2
6.2.3.4 Cisplatin	2
6.2.3.5 Docetaxel	2
6.2.3.6 Methotrexate	2
6.2.3.7 Mitomycin C	2
6.2.3.8 Nivolumab	2

6.2.3.9 Paclitaxel/nab-paclitaxel .....	2
6.2.3.10 Pembrolizumab .....	3
6.3 Special situations .....	3
6.3.1 Bone metastases .....	3
<b>7 Rehabilitation</b> .....	<b>3</b>
<b>8 Follow-up</b> .....	<b>3</b>
<b>9 References</b> .....	<b>3</b>
<b>10 Authors' Affiliations</b> .....	<b>3</b>
<b>11 Disclosures</b> .....	<b>3</b>

# Head and neck squamous cell carcinomas

**Date of document:** October 2022

## **Compliance rules:**

- [Guideline](#)
- [Conflict of interests](#)

**Authors:** Konrad Klinghammer, Melanie Boxberg, Peter Brossart, Wilfried Budach, Andreas Dietz, Michael Flentje, Viktor Grünwald, Orlando Guntinas-Lichius, Dennis Hahn, Max Heiland, Korinna Jöhrens, Maren Knödler, Florian Kocher, Sacha Rothschild, Bernhard Wörmann, Georg Maschmeyer

## **1 Summary**

Head and neck carcinomas represent a heterogeneous group of tumors between the skull base and the clavicle with sometimes very different etiologic factors and treatment principles. In this guideline, reference is made exclusively to squamous cell carcinomas arising in the oral cavity, lip, oropharynx, hypopharynx, and larynx, while nasopharyngeal, nasal cavity/paranasal sinus, and salivary gland carcinomas are not addressed. 90% of head and neck carcinomas in the upper aerodigestive tract discussed here are squamous cell carcinomas, and for 75% of these tumors, there is an association with nicotine and alcohol use. Whereas until a few decades ago, all head and neck carcinomas were grouped together, currently, comparable to other oncological diagnoses, there is an increasing diversification driven by different tumor biology and prognosis of the diseases. An example are the HPV-associated carcinomas of the oropharynx, which occur more frequently in younger patients, show less association with nicotine and alcohol, and have a significantly better prognosis than HPV-negative tumors.

In patients with head and neck tumors, a curative treatment approach is pursued in early and in some locally advanced stages. Therapeutic options are surgery, radiation, chemotherapy and immunotherapy, mostly combined as multimodal treatment concepts. Close multidisciplinary cooperation is a prerequisite for the optimal treatment of patients with head and neck tumors. Relevant innovations in recent years are the clearly emphasized transoral resection procedures, such as laser microsurgery (TLM) and robot-assisted surgery (TORS), the one-stage coverage of even complex defects with the help of patient-specific implants, the use of modern tissue-sparing radiation techniques, and the introduction of immunotherapy in the treatment concepts.

## **2 Basics**

### **2.1 Definition and basic information**

Head and neck squamous cell carcinomas (HNSCC) are epithelial malignancies originating primarily in the upper aerodigestive tract. Therapy-oriented guidelines differentiate according to localization, histological, and rarely also genetic and immunohistochemical parameters.

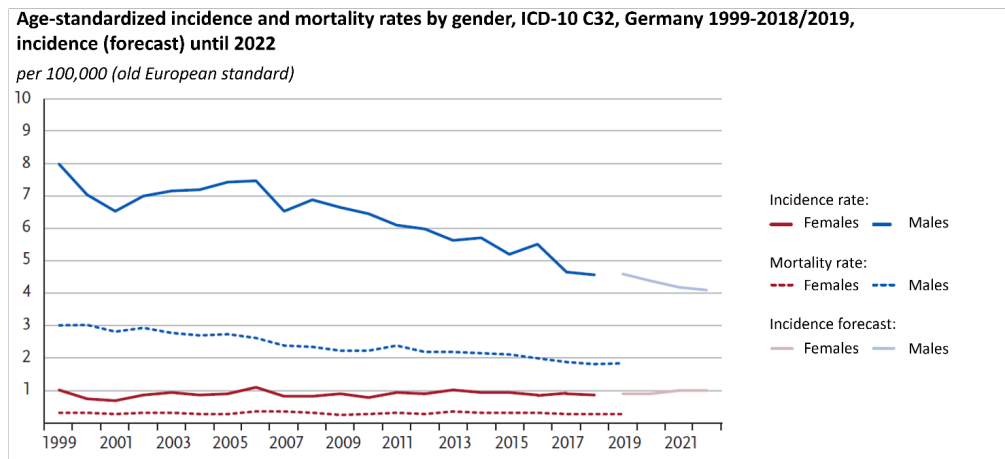
### **2.2 Epidemiology (Figures 1-4)**

Incidence and mortality for HNSCC have not changed significantly since 2000, with a decrease in new cases in men compared to a slight increase in incidence in women, especially for laryngeal cancer, but also for oral cavity and pharyngeal carcinoma, since 2011. According to data from the German Cancer Registry, 12,660 men and 4,560 women developed head and neck cancer in Germany in 2014. In 2015, 5,504 men (43%) and 1,659 women (36%) died from their

tumor disease. HNSCC is the fourth most common tumor in Germany in men at approximately 5%, with an age-standardized mortality of 6.7 per 100,000 population. In women, this rate is lower at 1.8 per 100,000 [1- 3].

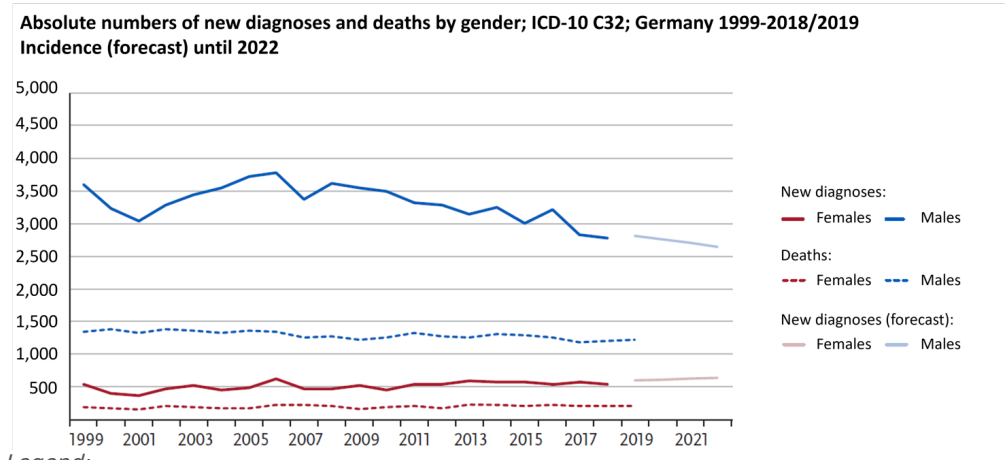
Due to anti-smoking campaigns, a decrease of the disease is shown in the USA, whereas in Germany this trend is not observed due to a lack of effective programs. Smoking is associated with a worse prognosis in patients with HPV-associated oropharyngeal carcinoma, comparable to HPV-negative carcinomas.

**Figure 1: Incidence and mortality of laryngeal carcinoma in Germany (age-standardized rate)**



Legend:  
Source: Center for Cancer Registry Data (Robert-Koch Institute) as of 31 October 2022

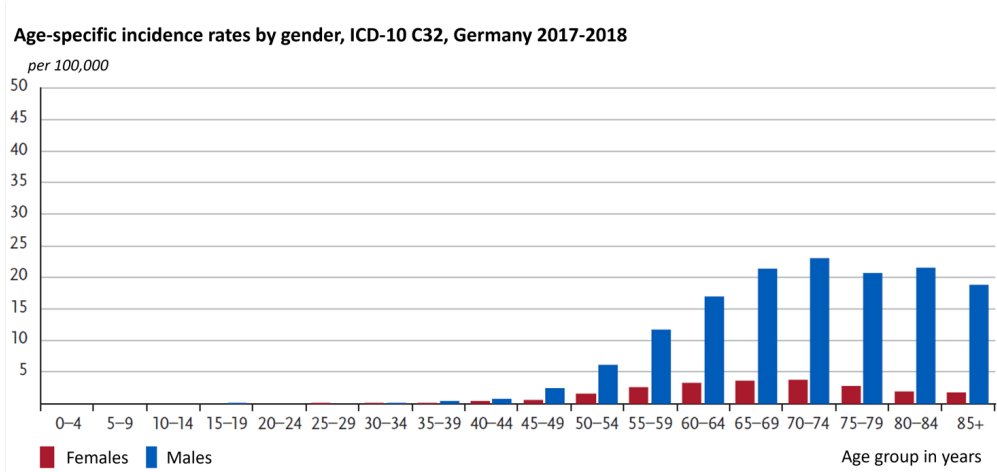
**Figure 2: Laryngeal carcinoma in Germany: numbers of new diagnoses and deaths**



Legend:  
Source: Center for Cancer Registry Data (Robert-Koch Institute) as of 31 October 2022

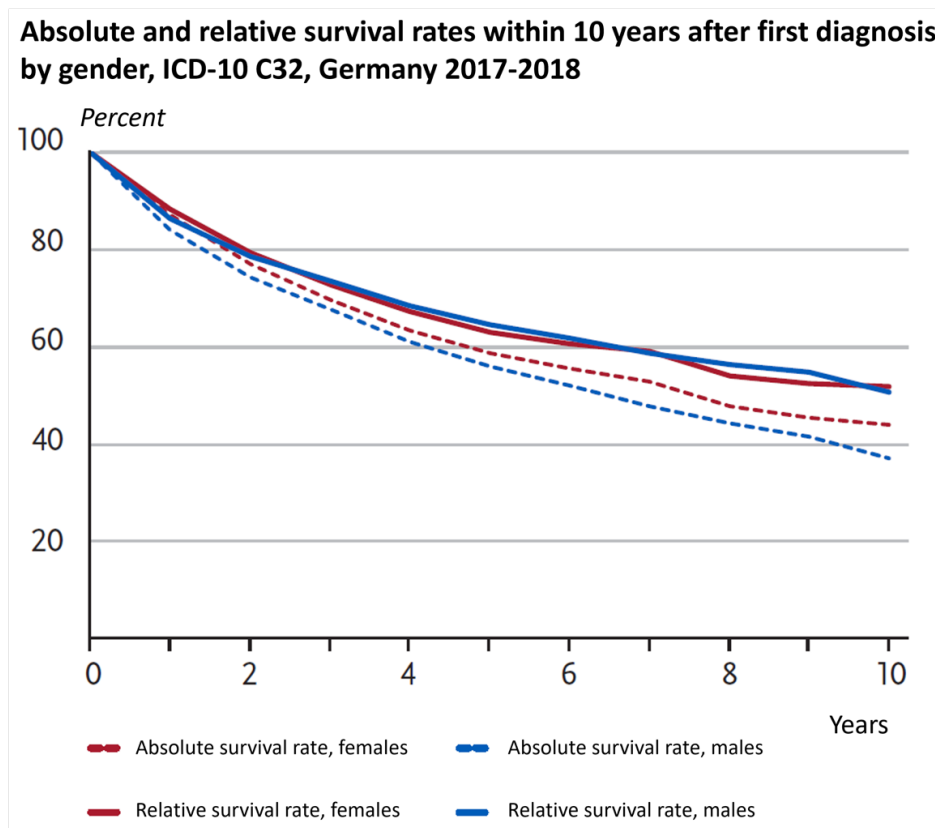
The mean age of onset at diagnosis is 63 years for men and 65 years for women, which is 7 years (men) and 4 years (women) below the mean age of onset for cancer overall. The median age at death for the most common location in the oral cavity and pharynx is 66 years (men) and 72 years (women). Most cases of oral cavity and pharyngeal cancer occur in men between 60 and 70 years of age, whereas in women, cases are fairly constant from 55 years of age onward, with a slight peak in those over 85 years of age. The number of new cases per age group depends on the age-specific risk of disease, but also on the age structure of the population. This results in apparent discrepancies between the risk of disease and the number of cases.

**Figure 3: Laryngeal carcinoma in Germany: age-specific incidence rates by gender**



Legend:  
 Source: Center for Cancer Registry Data (Robert-Koch Institute) as of 31 October 2022

**Figure 4: Laryngeal carcinoma in Germany: absolute and relative survival within 10 years after diagnosis, by gender**



Legend:  
 Source: Center for Cancer Registry Data (Robert-Koch Institute) as of 31 October 2022

## 2.3 Pathogenesis

Invasive HNSCC develop in the vast majority by two main routes: on the one hand, these tumors arise in connection with tobacco and alcohol consumption and, on the other hand, through infection with human papillomaviruses, in particular HPV-16. Tumors of the head and neck region develop in a complex, stepwise process through the accumulation of genetic alterations. In particular, the inactivation of tumor suppressor genes and the activation of proto-oncogenes play a role, which result in genetic instability. While the carcinogenesis of toxin-associated tumors is a complex process, the tumorigenesis of HPV-associated carcinomas fol-

lows a pattern in which the expression of the viral proteins E6 and E7 leads to the inactivation of p53 and Rb [4].

## 2.4 Risk factors

The risk of developing HNSCC is increased by the following factors:

- Alcohol consumption [5]
- Smoking [6- 8]
- HPV (exclusively in the oropharynx) [9]
- Poor oral hygiene [10]
- Chronic infection [10, 11]
- Chronic mechanical irritation [12]
- Betel nut consumption (oral cavity carcinoma) [13]
- Positive family history for head and neck tumors [14].
- Long-term immunosuppression [15]
- Rare: Fanconi anemia, Li-Fraumeni syndrome, Bloom's syndrome, ataxia teleangiectatica, congenital dyskeratosis, lichen ruber planus.

In particular, smoking and regular alcohol consumption are by far the most important risk factors, as they potentiate each other [16].

## 3 Prevention and early detection

### 3.1 Prevention

The general recommendations for prevention refer to the previously identified risk factors of smoking and regular alcohol consumption.

### 3.2 Early detection

Patients with Fanconi anemia are recommended to be enrolled in a regular screening program.

## 4 Clinical image

Symptoms depend on the localization of the tumor disease. Common to all localizations may be clinical signs such as weight loss, pain, dysphagia, odynophagia, and hemoptysis.

Specific symptoms are summarized in [Table 1](#).

**Table 1: Localization-dependent symptoms in patients with head and neck squamous cell carcinoma**

Cause	Symptom
Oral cavity	• Non-healing ulcers, tooth loosening, dysarthria as a sign of invasion of deep muscle layers, leukoplakia
Oropharynx	• Oropharynx: sleep apnea syndrome, throat swelling, globus sensation
Hypopharynx	• Hypopharynx: Otagia due to the affection of cranial nerves V, VII, IX and X
Larynx	• Hoarseness, stridor

## 5 Diagnosis

### 5.1 Diagnostic procedures

In addition to a detailed medical history, a combination of inspection, palpation and mirror examination or flexible laryngoscopy is part of the standard diagnostic procedures. In addition, performance status, nutritional status, psychosocial history, dental status, and assessment of speech and swallowing function should be obtained. In patients over 70 years of age, a geriatric assessment is also recommended. Panendoscopy (endoscopy of the pharyngeal area, trachea and upper bronchi, and esophagus) under anesthesia is an important component of staging procedures for tumors of the larynx and pharynx and is used for histological confirmation, reliable size assessment before definitive therapy, and exclusion of synchronous second malignancies.

CT or MRI of the neck should be performed to exclude metastases and to assess resectability. Especially in advanced tumors, extended diagnostics by CT of the thorax and abdomen are recommended to detect any distant metastases or second malignancies. CT is superior to MRI with regard to the detection of lymph node metastases, whereas MRI is better at imaging perineural tumor invasion, cartilage involvement, and intracranial infiltration. These two techniques should therefore be considered complementary. In cases of suspected lymph node (LN) metastasis and undetectable primary, fine-needle biopsy of the lymph nodes should be sought.

PET-CT is superior to CT for the detection of occult lymphatic metastases. As in general for cross-sectional imaging, but especially for PET-CT, due to false negative findings in metastases < 5 mm, the procedure cannot stratify for or against definitive treatment of lymphatic pathways [17].

Recommendations for diagnosis and staging are summarized in [Table 2](#).

**Table 2: Diagnostic procedures for suspected HNSCC and subsequent staging**

Procedure	Note
Physical examination	Including an examination of the head and neck
Laboratory (blood)	Blood counts, liver and kidney function parameters, coagulation, TSH
Laryngoscopy; ENT; Panendoscopy	For surgical treatment planning and exclusion of other neoplasms; no panendoscopy in oral cavity carcinoma
Histology	Histopathological findings
Dental status	Before an examination under anesthesia or surgical tumor therapy, in order to complete repair as early as possible
Computed tomography neck (or alternatively MRI neck), thorax, abdomen with contrast medium	If indicated, in combination with PET
Sonography abdomen and neck	If indicated, complementary to computed tomography
Positron emission tomography - computed tomography (PET-CT)	Exclusion of distant metastases, planning of surgery, planning of radiotherapy
Bronchoscopy and esophagoscopy	No standard procedure, but indicated in case of specific symptoms or diagnostic findings (e.g., to exclude secondary neoplasms or a tracheobronchial fistula).
Functional assessment of important organ functions	Clarification of functional operability and assessment of potential therapy-related toxicities before systemic therapy and/or RT.
Screening for malnutrition	

PET-CT may allow to detect occult distant metastases and thus modify the therapeutic procedure in the case of an otherwise resectable primary tumor and, in particular, determine the procedure for surgical removal of neck lymph nodes. In Germany, PET-CT is reimbursed on the basis of a decision by the Joint Federal Committee in the situation where a decision is to be made after primary radiochemotherapy, as to whether neck lymph nodes must be removed [18]. In addition, it is important for the search for occult primary tumors in cervical lymph node metastasis and in follow-up, when it is necessary to differentiate between therapy-induced tissue senescence and tumor recurrence.

## **5.2 Classification**

### **5.2.1 Stages**

The current UICC/TNM classification for lip, oral cavity carcinoma and for p16-negative oropharyngeal carcinoma is depicted in [Table 3](#), and for p16-positive oropharyngeal carcinoma in [Table 4](#).

**Table 3: UICC/TNM classification for lip, oral cavity and for p16-negative oropharyngeal carcinoma (modified after: <https://www.cancer.org/cancer/oral-cavity-and-oropharyngeal-cancer/detection-diagnosis-staging/staging.html>)**

UICC stage	Stage grouping	Lip, oral cavity and p16 (HPV)-negative oropharynx cancer stage description*
<b>0</b>	<b>Tis N0 M0</b>	The cancer is still within the epithelium (the top layer of cells lining the oral cavity and oropharynx) and has not yet grown into deeper layers. It has not spread to nearby lymph nodes (N0) or distant sites (M0). This stage is also known as carcinoma <b>in situ</b> (Tis).
<b>I</b>	<b>T1 N0 M0</b>	The cancer is 2 cm or smaller. It is not growing into nearby tissues (T1). It has not spread to nearby lymph nodes (N0) or to distant sites (M0).
<b>II</b>	<b>T2 N0 M0</b>	The cancer is larger than 2 cm but no larger than 4 cm. It is not growing into nearby tissues (T2). It has not spread to nearby lymph nodes (N0) or to distant sites (M0).
<b>III</b>	<b>T3 N0 M0</b>	The cancer is larger than 4 cm (T3). For cancers of the oropharynx, T3 also includes tumors that are growing into the epiglottis (the base of the tongue). It has not spread to nearby lymph nodes (N0) or to distant sites (M0).
	OR	
	<b>T1, T2, T3 N1 M0</b>	The cancer is any size and may have grown into nearby structures if oropharynx cancer(T1-T3) <b>AND</b> has spread to 1 lymph node on the same side as the primary tumor. The cancer has not grown outside of the lymph node and the lymph node is no larger than 3 cm (N1). It has not spread to distant sites (M0).
<b>IVA</b>	<b>T4a N0 or N1 M0</b>	The cancer is any size and is growing into nearby structures such as: <ul style="list-style-type: none"> <li>• For lip cancers: nearby bone, the inferior alveolar nerve (the nerve to the jawbone), the floor of the mouth, or the skin of the chin or nose (T4a)</li> <li>• For oral cavity cancers: the bones of the jaw or face, deep muscle of the tongue, skin of the face, or the maxillary sinus (T4a)</li> <li>• For oropharyngeal cancers: the larynx (voice box), the tongue muscle, or bones such as the medial pterygoid, the hard palate, or the jaw (T4a).</li> </ul> This is known as moderately advanced local disease (T4a). <b>AND</b> either of the following: <ul style="list-style-type: none"> <li>• It has not spread to nearby lymph nodes (N0)</li> <li>• It has spread to 1 lymph node on the same side as the primary tumor, but has not grown outside of the lymph node and the lymph node is no larger than 3 cm (N1).</li> </ul> It has not spread to distant sites (M0).
	OR	
	<b>T1, T2, T3 or T4a N2 M0</b>	The cancer is any size and may have grown into nearby structures (T0-T4a). It has not spread to distant organs (M0). It has spread to one of the following: <ul style="list-style-type: none"> <li>• One lymph node on the same side as the primary tumor, but it has not grown outside of the lymph node and the lymph node is larger than 3 cm but not larger than 6 cm (N2a) <b>OR</b></li> <li>• It has spread to more than 1 lymph node on the same side as the primary tumor, but it has not grown outside any of the lymph nodes and none are larger than 6 cm (N2b) <b>OR</b></li> <li>• It has spread to 1 or more lymph nodes either on the opposite side of the primary tumor or on both sides of the neck, but has not grown outside any of the lymph nodes and none are larger than 6 cm (N2c).</li> </ul>
<b>IVB</b>	<b>Any T N3 M0</b>	The cancer is any size and may have grown into nearby soft tissues or structures (Any T) <b>AND</b> any of the following: <ul style="list-style-type: none"> <li>• It has spread to 1 lymph node that is larger than 6 cm but has not grown outside of the lymph node (N3a) <b>OR</b></li> <li>• It has spread to 1 lymph node that's larger than 3 cm and has clearly grown outside the lymph node (N3b) <b>OR</b></li> <li>• It has spread to more than 1 lymph node on the same side, the opposite side, or both sides of the primary cancer with growth outside of the lymph node(s) (N3b) <b>OR</b></li> <li>• It has spread to 1 lymph node on the opposite side of the primary cancer that is 3 cm or smaller and has grown outside of the lymph node (N3b).</li> </ul> It has not spread to distant organs (M0).
	OR	
	<b>T4b Any N M0</b>	The cancer is any size and is growing into nearby structures such as the base of the skull or other bones nearby, or it surrounds the carotid artery. This is known as <b>very advanced local disease</b> (T4b). It might or might not have spread to nearby lymph nodes (Any N). It has not spread to distant organs (M0).
<b>IVC</b>	<b>Any T Any N M1</b>	The cancer is any size and may have grown into nearby soft tissues or structures (Any T) <b>AND</b> it might or might not have spread to nearby lymph nodes (Any N). It has spread to distant sites such as the lungs (M1).

**Table 4: UICC/TNM classification for p16-positive oropharyngeal carcinoma (modified after: <https://www.cancer.org/cancer/oral-cavity-and-oropharyngeal-cancer/detection-diagnosis-staging/staging.html>)**

AJCC stage	Stage grouping	p16 (HPV)-positive oropharynx cancer stage description*
I	<b>T0, T1 or T2 N0 or N1 M0</b>	The cancer is no larger than 4 cm (T0 to T2) <b>AND</b> any of the following: <ul style="list-style-type: none"> <li>• It has not spread to nearby lymph nodes (N0) <b>OR</b></li> <li>• It has spread to 1 or more lymph nodes on the same side as the primary cancer, and none are larger than 6 cm (N1).</li> </ul> It has not spread to distant sites (M0).
II	<b>T0, T1 or T2 N2 M0</b>	The cancer is no larger than 4 cm (T0 to T2) <b>AND</b> it has spread to 1 or more lymph nodes on the opposite side of the primary cancer or both sides of the neck, and none are larger than 6 cm (N2). It has not spread to distant sites (M0).
	<b>T3 or T4 N0 or N1 M0</b>	The cancer is larger than 4 cm (T3) <b>OR</b> is growing into the epiglottis (the base of the tongue) (T3) <b>OR</b> is growing into the larynx (voice box), the tongue muscle, or bones such as the medial pterygoid plate, the hard palate, or the jaw (T4) <b>AND</b> any of the following: <ul style="list-style-type: none"> <li>• It has not spread to nearby lymph nodes (N0) <b>OR</b></li> <li>• It has spread to 1 or more lymph nodes on the same side as the primary cancer, and none are larger than 6 cm (N1).</li> </ul> It has not spread to distant sites (M0).
III	<b>T3 or T4 N2 M0</b>	The cancer is larger than 4 cm (T3) <b>OR</b> is growing into the epiglottis (the base of the tongue) (T3) <b>OR</b> is growing into the larynx (voice box), the tongue muscle, or bones such as the medial pterygoid plate, the hard palate, or the jaw (T4) <b>AND</b> it has spread to 1 or more lymph nodes on the opposite side of the primary cancer or both sides of the neck, and none are larger than 6 cm (N2). It has not spread to distant sites (M0).
IV	<b>Any T Any N M1</b>	The cancer is any size and may have grown into nearby structures (Any T) <b>AND</b> it might or might not have spread to nearby lymph nodes (Any N). It has spread to distant sites such as the lungs or bones (M1).

Legend:

\* The following additional categories are not described in the Tables above:

- **TX:** Main tumor cannot be assessed due to lack of information.
- **T0:** No evidence of a primary tumor.
- **NX:** Regional lymph nodes cannot be assessed due to lack of information.

## 5.2.2 Histology

### 5.2.2.1 WHO classification

Diagnosis is usually made by biopsy of the primary or an accessible lymph node metastasis.

HNSCCs are evaluated according to the current 4th edition of the WHO classification. The classification defines subtypes with prognostic relevance (verrucous/basaloid/sarcomatoid/"conventional"). The "conventional" carcinomas (keratinizing/non-keratinizing) are graded according to their similarity to regular squamous epithelium (G1/G2/G3), but it should be mentioned that according to the WHO classification the prognostic significance of this grading is very limited. Tumors of the oropharynx have a special role, since HPV testing should be performed for all of them. For this purpose, immunohistochemical staining for p16 is recommended in the WHO classification and is accepted as a surrogate marker for HPV positivity in the oropharynx (includes tonsils and base of tongue). In this context, a tumor at this localization is considered positive, if more than 70% of the tumor cells show nuclear and/or cytoplasmic staining. Other test methods include, for example, PCR testing or RNA detection. It should be noted that HPV-associated HNSCC are not graded. Due to the per se fragmented basement membrane in lymphoepithelial tissue, no precursor lesions (carcinoma in situ) are defined for these carcinomas - they are always rated as invasive.

### 5.2.2.2 TNM/UICC classification

The pathological workup of resected tissue specimens should include pathological staging according to the current TNM/UICC classification, see also Chapter 5.2.1. This includes the following parameters:

1. Tumor size (pT1-4), with additional specification of depth of invasion for oral HNSCC.
2. Nodal status: in oropharyngeal carcinomas distinct for p16-negative and p16-positive oropharyngeal carcinomas.
  1. Nodal status for all carcinomas of the head and neck and for the p16-negative oropharyngeal carcinomas (pN1-3), which includes the number of resected and the number of affected lymph nodes and their location. Regarding the lymph nodes, the size of the largest metastasis and an assessment of extracapsular extension (ECE) should be provided.
  2. Nodal status (pN1-pN2) for the p16-negative oropharyngeal carcinomas, where only the number of affected lymph nodes (pN1: up to 4 LN or pN2: 5 or more LN) is taken into account, but not the size or extracapsular infiltration.
3. Grading: G1/ G2/ G3.
4. Perineural sheath infiltration (Pn), lymphangiosis or haemangiosis carcinomatosa (L or V, respectively). These parameters are classified as present or absent.
5. Resection status (R0/R1/Rx): The width of the tumor-free resection margins must also be specified.

These parameters are considered prognostically significant determinants of adjuvant treatment stratification. As mentioned above, this applies to the significance of grading only to a limited extent. It should be noted that the current TNM classification classifies p16-negative and p16-positive HNSCC as separate entities in distinct systems.

### 5.2.2.3 Other parameters

In addition to these obligatory parameters, a statement regarding the growth pattern of the carcinoma is recommended. The prognostic significance of tumor budding has been proven in many studies, so that it can be assumed that this could be included in the guidelines in the future. Tumor budding can be specified as absent/weak/strong.

A special entity are so-called "cancers of unknown primary (CUP)". These are squamous-cell lymph node metastases in patients with no detectable primary tumor. Here, p16 immunohistochemistry and EBV in situ hybridization are recommended as standard. Positivity may indicate small HPV-associated HNSCC or EBV-associated nasopharyngeal carcinoma as the primary. CUP in which no primary tumor can be found even by these and other ancillary investigations, are addressed in a separate scheme in the current UICC/TNM classification.

In relapsed or metastatic HNSCC, PD-L1 expression status should be determined by immunohistochemistry. In the current regulatory situation in Germany (as of August 2022), the combined positive score (CPS) is used as a predictive biomarker; a score  $\geq 1$  is classified as positive. A CPS score of  $\geq 20$  may be particularly relevant for therapy stratification. For this reason, the calculated CPS value should always be reported.

## 6 Therapy

### 6.1 Treatment with curative intention

#### 6.1.1 Multidisciplinary approach

In the treatment of locoregionally limited HNSCCs, radiotherapy is a curative adjuvant treatment approach, either alone or in combination with systemic therapy, in addition to surgery. Due to complex treatment options, recommendations should always be discussed and decided on a multidisciplinary basis (multidisciplinary tumor board). In very early tumor stages (T1-2 N0 M0), surgery alone or radiotherapy are available. The treatment decision depends largely on functional aspects and individual patient tolerance. In addition to tumor-specific factors, these patient-specific factors play a special role, since typical HNSCC-associated comorbidities with potential cardiovascular, pulmonary or hepatic limitations are often present, may significantly complicate therapy and can lead to de facto inoperability in tumors despite surgical resectability [19].

#### 6.1.2 Surgery

A first-line surgical approach is recommended for T3/T4 oral cavity carcinomas. Advanced hypopharyngeal carcinomas should upfront be treated surgically, especially in the presence of cartilage invasion. For T3/T4a tumors of the larynx and hypopharynx, the possibility of laryngeal preservation should be discussed in the multidisciplinary tumor board (20). In early T stages and selected cases of advanced T stages, a transoral approach is favored, when technically feasible, because of the lower treatment-associated morbidity. Here, procedures with classical cold instruments, laser surgery, and transoral robotic surgery are used. Depending on the expected tissue defect and functional loss, reconstructive surgery with regional-flap plasty or free-flap plasty is performed. The standard of surgical treatment of the neck soft tissues is neck dissection. The extent and radicality depends on the tumor entity, T and N stage. Salvage surgery may be indicated for tumor progression under/after primary radio(chemo)therapy or for resectable recurrent tumors.

#### 6.1.3 Radiotherapy

Radiotherapy pursues a curative therapeutic approach using at least 60 Gray (Gy); usually >66 Gy are given in single doses of 2 Gy. Three-dimensional conformal planning of the irradiation fields is a prerequisite for curative radiation therapy. Procedures such as intensity-modulated radiation therapy (IMRT) or image-guided radiation therapy (IGRT) reduce the morbidity of irradiation, so that these procedures are now routinely used.

In advanced stages III, IVa and IVb, simultaneous radiochemotherapy (RCT) is the therapeutic standard instead of radiotherapy alone. Doses of 70 Gy, 72-76.8 Gy, and 72 Gy, respectively, are used depending on the radiation technique (1 × 2 Gy daily, 2 × 1.2 Gy daily, or "concomitant boost"). This therapeutic approach has been particularly well studied in tumors of the oropharynx and larynx in stages III and IV of non-metastatic disease.

Numerous studies have evaluated the efficacy of cisplatin in combination with radiation. The MACH-NC meta-analysis included individual patient data from 93 randomized trials with a total of 17,346 patients [21]. Chemotherapy was given either as induction therapy, concurrently, or sequentially after locoregional therapy. Simultaneous RCT proved to be the most favorable procedure. In 50 randomized trials of simultaneous RCT involving 9,615 patients, the hazard ratio for mortality decreased to 0.81 ( $p < 0.0001$ ) compared with radiotherapy alone, and the

absolute survival gain at 5 years was 6.5% [21]. In most studies, cisplatin ± 5-fluorouracil (5-FU) was combined with radiotherapy. Here, cisplatin was usually given at a dose of 100 mg/m<sup>2</sup> body surface area three times during radiotherapy (total dose 300 mg/m<sup>2</sup>). In the only negative study, cisplatin was obviously underdosed with a total of 20 mg/m<sup>2</sup> weekly × 7 [21]. In patients over 70 years of age, although the number of patients studied was small, no survival benefit was demonstrated by concurrent chemotherapy in randomized trials. In contrast, large prospective databases show a survival benefit even in >70-year-old patients, if they were in a good general condition (ECOG Performance Score 0-1). Therefore, the indication for concurrent chemotherapy in elderly patients must be discussed very thoroughly [22].

Regarding the choice of the concurrent chemotherapy, no clinically relevant differences were demonstrated between therapy with cisplatin alone or cis- or carboplatin in combination with 5-FU. Therapy without cis-/carboplatin and 5-FU is not recommended. In the presence of contraindications to platinum, mitomycin C +/- 5 FU may be combined with radiotherapy [23, 24]. In contrast to the initial favorable data of the “Bonner study” for oropharyngeal carcinoma [6], current data show inferiority of cetuximab compared with cisplatin therapy [25- 27].

Prospective databases and a meta-analysis also show inferiority of cetuximab to cisplatin in HPV-negative tumors [28].

In an evaluation by the MACH-NC group, the benefit of RCT was again confirmed. By including large numbers of patients, the absolute survival gain by RCT compared to radiotherapy alone could also be demonstrated for the individual tumor localizations. After 5 years, the absolute survival gain after RCT was 8.9% for tumors of the oral cavity, 8.1% for oropharyngeal cancer, 5.4% for laryngeal cancer, and 4% for carcinomas of the hypopharynx [29]. When compared to regimens with 3 weekly administration of cisplatin 100mg/m<sup>2</sup>, current data indicate that weekly administration of cisplatin in a dosage of 40mg/m<sup>2</sup> appears non-inferior but better tolerated. A minimum cumulative dose > 200mg/m<sup>2</sup>, however, seems important in this setting [30, 31].

Due to the better prognosis of HPV-positive oropharyngeal carcinomas, the question of de-intensifying RCT by replacing cisplatin with cetuximab was raised. The NRG-RTOG-1016 phase III trial failed to demonstrate noninferiority of cetuximab. Patients treated with radiotherapy plus cetuximab had a higher rate of locoregional recurrence (17 vs. 10%) and lower 5-year survival (78% vs. 85%) [32, 33].

The use of immune checkpoint inhibitors has been studied in several phase II/III trials in combination with radiation in advanced tumors. As a result of the study results, their use cannot be recommended so far [34- 36].

Preoperative radiotherapy alone, in order to improve resectability and eliminate microscopic tumor portions outside the resection margins, has not been successful.

If R0 resection could be performed, adjuvant radiotherapy or radiochemotherapy should be administered for the following indications:

Indication for adjuvant radiotherapy is based on the presence of risk factors:

- pT ≥3
- pN2 or pN3 or >1 LN (pN1) with HPV positivity
- Perineural invasion (Pn1)
- Lymphovascular invasion (V1)

Indication for radiochemotherapy:

- Extracapsular extension (ECE+)

- Tumor-free resection margin < 5 mm or R1

Adjuvant treatment should be given within 6 weeks post-resection, provided there are no wound healing problems.

The extent to which the addition of cisplatin chemotherapy in advanced stage III or IV tumors results in prolonged survival is controversial. Weekly administration of cisplatin at 40 mg/m<sup>2</sup> is noninferior to 3-weekly administration at 100 mg/m<sup>2</sup> [37]. Postoperative RCT resulted in improved local control compared with radiotherapy alone, as demonstrated in two large independent trials (EORTC 22931; n = 334 and RTOG 9501; n = 459). However, at 10-year follow-up, only the high-risk group of patients with extracapsular extension and positive resection margin showed a persistent significant difference in terms of disease-free survival and local control. For patients with increased risk of recurrence based on T3 and T4 tumors, perineural or vascular invasion, and two or more affected lymph nodes, the addition of chemotherapy to radiotherapy is not unequivocally beneficial because of the nonsignificant differences in disease-free survival and local control.

#### **6.1.4 Adjuvant systemic therapy**

According to a meta-analysis including a total of about 2,500 patients, adjuvant chemotherapy alone after successful primary therapy (R0 resection) is not indicated, since the 5-year survival rate of 48.4% was not better than that in the control arm with 49.4% [38, 39]. Data on the adjuvant use of checkpoint inhibitors are currently not available.

#### **6.1.5 Induction chemotherapy**

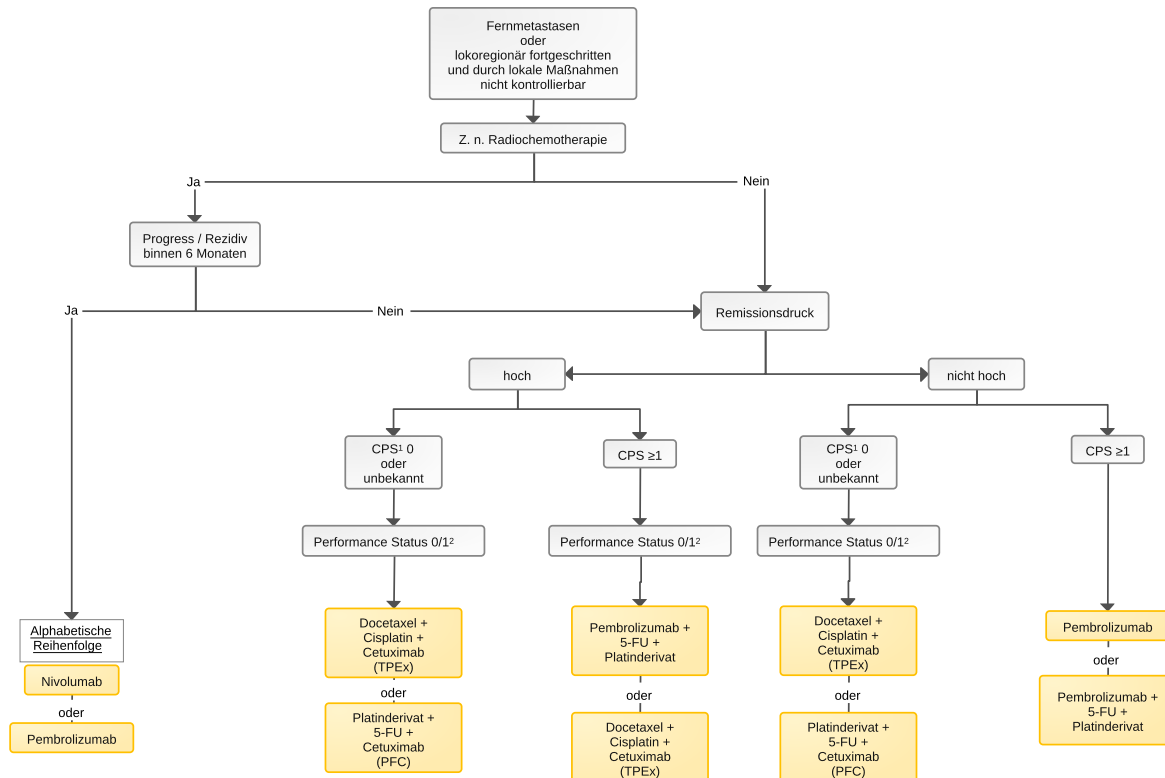
Primary chemotherapy of locally advanced but not metastatic HNSCC was shown to be highly effective in historical trials with remission rates of  $\geq 80\%$ , but it was not clear whether this approach leads to better long-term outcomes than simultaneous RCT. Through meta-analysis of 31 trials with 5,311 patients, who received locoregional treatment immediately or only after induction chemotherapy (ICT), a marginal increase in 5-year survival from 30% to 32.4% was demonstrated for induction therapy [21]. The comparison between induction and simultaneous radiochemotherapy also indicates a superior effectiveness of simultaneous RCT.

Two meta-analyses evaluating individual data from a combined total of 33 randomized trials with a total of 5,211 patients demonstrated that induction therapy reduced distant metastasis rates by 8% in patients with head and neck cancer, but did not affect local control or overall survival [40, 41]. For laryngeal preservation in very advanced tumors that would require laryngectomy or pharyngectomy, induction chemotherapy followed by radiotherapy alone may be used. Larynx preservation rates are higher using induction followed by radiochemotherapy, but associated with increased toxicity and comparable survival rates [42]. The randomized TAX323 trial evaluated the superiority of a combination of docetaxel, cisplatin, and 5-FU (TPF) for induction chemotherapy over the two-drug combination of cisplatin and 5-FU (PF). The study showed a survival benefit in favor of TPF, albeit with high toxicity [43]. Follow-up after the first cycle by imaging and panendoscopy allows assessment of the likelihood of success of laryngeal preservation, and a tumor size reduction of  $\geq 30\%$  should be achieved to justify continuation of induction chemotherapy for a total of 3 cycles [44]. Patients with advanced infiltration of the laryngeal cartilage should be offered a primary surgical approach including laryngectomy. In other localizations of HNSCC beyond the larynx, ICT has not demonstrated a benefit at this time [45]. Currently, studies are investigating the use of PD-1 inhibitors in the neoadjuvant setting.

## **6.2 Therapy with non-curative intention**

An algorithm for first-line therapy in non-curative intention is shown in [Figure 5](#).

**Figure 5: Palliative first-line therapy**



Legend:

<sup>1</sup> CPS = Combined Positive Score;

<sup>2</sup> Performance Status according to ECOG (Eastern Cooperative Oncology Group)

### 6.2.1 First-line treatment

In the presence of distant metastases or locoregionally advanced disease that cannot be controlled by surgery or radiotherapy, palliative systemic therapy should be offered, if the patient is in a good general condition (ECOG PS 0-2). Overall survival with palliative systemic therapy is between 12 and 15 months on median [46- 48]. In case of oligometastasis, the option of surgery or radiotherapy in addition to or instead of systemic therapy should be discussed in a multidisciplinary tumor board.

In most cases, partial remission of the tumor is achieved by chemotherapy. Complete remissions are rare. The goal of therapy, in addition to prolonging survival, is to maintain or improve the quality of life.

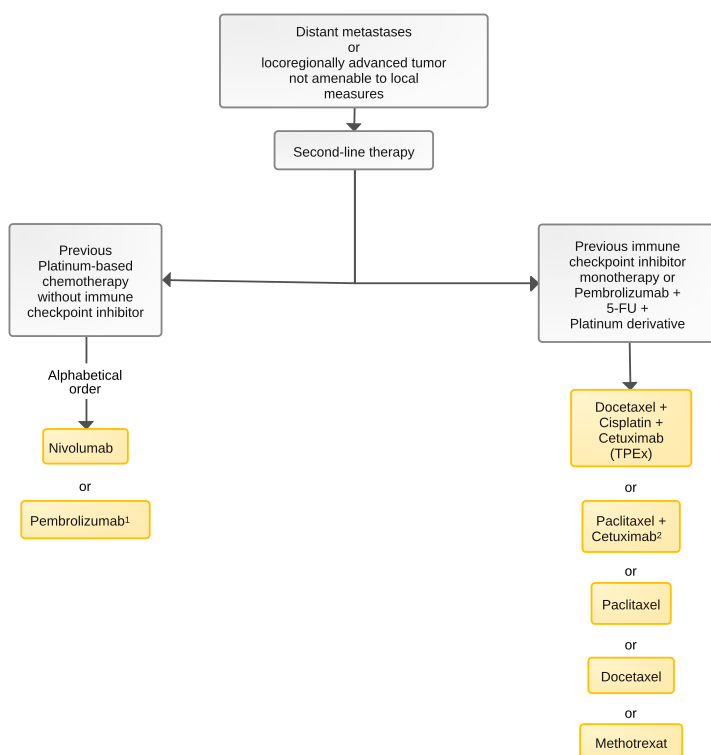
The standard for first-line palliative therapy has fundamentally changed with the Keynote-048 trial and TPEX extreme trial. The Keynote-048 trial randomized the long-standing standard of care of the Extreme protocol with cisplatin, 5-FU, and cetuximab (PF-C) followed by cetuximab maintenance [43] against the immune checkpoint inhibitor pembrolizumab alone or in combination with cisplatin, and 5-FU followed by pembrolizumab maintenance [46]. Pembrolizumab resulted in prolonged overall survival of 14.9 versus 10.7 months in monotherapy, especially in PD-L1 high-expressing tumors (CPS  $\geq 20$ ), with a significantly better side effect profile. However, the response rate was lower than with PF-C at 23.3% vs. 36.1%, and more patients were also primarily progressive with pembrolizumab monotherapy than with PF-C. With a CPS  $\geq 1$ , there is also an overall survival benefit of 12.3 months vs. 10.3 months, with 38.9% being primarily progressive in this group. With pembrolizumab, cisplatin, and 5-FU, overall survival is also significantly prolonged compared with PF-C for CPS  $\geq 1$ , with comparable remission rates. However, the rate of adverse events is comparable to Extreme and significantly higher than with pembrolizumab alone.

Regarding chemotherapy in combination with the anti-EGFR antibody cetuximab, a randomized phase II trial compared PF-C with the TPEX protocol (cisplatin, docetaxel, cetuximab), each followed by cetuximab maintenance [47]. Chemotherapy was shortened from 6 cycles to 4 cycles with TPEX, and the total cisplatin dose was reduced by 50% compared with PF-C. Overall survival was comparable with overall lower toxicity and shortened chemotherapy duration with TPEX. The response rate with the docetaxel-containing regimen was also comparable to the control arm at 57%, demonstrating the high efficacy of the regimen. Thus, TPEX can be used as an alternative first-line therapy to PF-C in patients in good general condition, remission pressure, high tumor burden, regardless of PD-L1 status. G-CSF administration was mandatory in the study treatment and is recommended for clinical practice.

## 6.2.2 Second-line treatment

An algorithm for second-line palliative therapy is shown in Figure 6.

**Figure 6: Palliative second-line therapy**



Legend:

<sup>1</sup> for PD-L1 TPS  $\geq 50\%$ ;

<sup>2</sup> off-label, if cetuximab is given without platinum

For patients with progression after platinum-containing chemotherapy, treatment with the anti-PD-1 immune checkpoint inhibitor nivolumab, compared with a monotherapy using a taxane (paclitaxel or docetaxel), methotrexate (MTX) or cetuximab, significantly prolonged survival to 7.5 versus 5.1 months [49]. Nivolumab is approved for this indication regardless of PD-L1 expression in HNSCC after failure of platinum-based therapy. In a comparable study design, similar results were obtained for the PD-1 inhibitor pembrolizumab, although (pre-specified) statistical significance was achieved only for the patient group with a PD-L1 TPS  $\geq 50\%$  [50]. For patients with a PD-L1 TPS  $\geq 50\%$ , median overall survival was significantly better at 11.6 months with pembrolizumab versus 6.6 months with a taxane, MTX, or cetuximab, resulting in an approval for patients with TPS  $\geq 50\%$  after failure platinum-based prior therapy.

In light of these study results, in the absence of contraindications to a checkpoint inhibitor in second-line therapy after P-FC or TPEX, treatment should be with nivolumab (regardless of PD-L1 expression) or pembrolizumab (TPS  $\geq 50\%$ ).

After first-line therapy with pembrolizumab mono or PF-pembrolizumab, there is no standard therapy established by study results. A retrospective analysis showed a high remission rate of 30% by salvage chemotherapy after checkpoint inhibition with a median overall survival of 7.6 months after a median of 2 prior therapies [51]. Thus, increased chemotherapy sensitivity after checkpoint inhibition can be hypothesized, however, no established sequential therapy approach has been established to date.

### **6.2.3 Systemic treatment agents (in alphabetical order)**

#### **6.2.3.1 -fluorouracil**

5-FU is used for systemic therapy of patients with head and neck cancers in the (neo-)adjuvant and metastatic setting. In contrast to therapy with 5-FU in other tumor entities, there is no indication that a combination with folinic acid will increase efficacy. Oral fluoropyrimidines such as capecitabine have no proven therapeutic relevance in HNSCCs. Serious adverse effects include diarrhea and stomatitis. Patients with functionally relevant polymorphisms of 5-FU degradation genes are at an increased risk for severe side effects including neutropenia and neutropenic fever. It is mandatory since 04/2020 to test all patients for dihydropyrimidine dehydrogenase (DPD) deficiency (either by measuring the level of uracil or by testing for the presence of specific polymorphisms) before starting treatment with 5-FU, according to the recommendations of the European Medicines Agency (EMA), and to implement appropriate therapeutic consequences depending on the results.

#### **6.2.3.2 Carboplatin**

Carboplatin can be used as an alternative in case of contraindications to cisplatin, especially with regards to nephrotoxicity. It has not yet been randomized against cisplatin, and cisplatin is standard in combination with radiotherapy and in palliative systemic therapy. For fit patients  $\geq$  70 years of age (geriatric assessment recommended), combination of carboplatin, 5-FU, and cetuximab showed a PFS of 7.2 mo. and an OS of 14.7 mo., so for fit elderly patients, when platinum, 5-FU plus cetuximab are used, the administration of carboplatin can be considered [52].

#### **6.2.3.3 Cetuximab**

Cetuximab competes with ligands for the binding site at the EGF receptor. If cetuximab binds, there is no phosphorylation of the tyrosine kinase and activation of the signaling cascade. In addition, internalization of the receptor and subsequent degradation occurs, resulting in a decrease in EGFR expression. A third mechanism, antibody dependent cellular cytotoxicity (ADCC), leads to the immigration of NK and cytotoxic T cells, resulting in lysis of antibody-bearing cells. A further antiproliferative effect is achieved by reduced release of angiogenic growth factors. The antibody was initially investigated in the "BONNER study" in combination with radiation in a curative setting. Radiochemotherapy showed significantly longer progression-free (24.4 vs. 14.9 months) and overall survival (49 vs. 29.3 months) compared with radiotherapy alone [53]. In the subsequent RTOG 0522 trial, cetuximab in combination with cisplatin and radiotherapy was compared with cisplatin radiotherapy alone. No benefit was obtained here for the addition of cetuximab in any of the relevant endpoints [54]. The EXTREME trial evaluated cetuximab in combination with chemotherapy in the palliative setting. The combination of platinum, 5-FU, and cetuximab resulted in significantly longer survival, becoming the new standard of care in the palliative setting [48]. Cetuximab was thus the first and, until 2017, the only approved targeted therapy in the treatment of HNSCC.

#### **6.2.3.4 Cisplatin**

Cisplatin is the treatment standard in combination with radiotherapy for locally advanced disease and is used in combination therapy in the palliative setting. In definitive radiochemotherapy, cisplatin is given as monotherapy and should reach a total dose of  $\geq 200$  mg/m<sup>2</sup>. Weekly administration of 40 mg/m<sup>2</sup> showed non-inferiority in overall survival and a better side effect profile than administration of 100 mg/m<sup>2</sup> every 3 weeks in a phase II/III study [55]. Fractionated administration of weekly cisplatin also showed noninferiority in the adjuvant setting [37]. The extent to which the previous standard of 100 mg/m<sup>2</sup> is superseded by these data in the definitive as well as the adjuvant setting is currently a matter of controversy. In palliative therapy, cisplatin is combined with 5-FU and pembrolizumab or with cetuximab plus 5-FU or docetaxel, achieving remission rates between 36% and 59% with a median overall survival of 13-14 months. Specific severe adverse effects (grade 3/4) include nausea and vomiting, nephrotoxicity, polyneuropathy, ototoxicity, hematotoxicity, electrolyte shifts, cardiotoxicity, and diarrhea.

#### **6.2.3.5 Docetaxel**

Docetaxel as a monotherapeutic agent, along with platinum derivatives, is one of the agents with the highest activity in HNSCC. As a monotherapy, studies have evaluated doses of 40 mg/m<sup>2</sup> weekly or 100 mg/m<sup>2</sup> every 3 weeks in patients with head and neck tumors. Objective response rates ranged from 27% to 32% in pretreated patients [56- 58]. In the TPex trial, docetaxel was combined with cisplatin and cetuximab. Based on the efficacy data and favorable toxicity profile, compared with cisplatin, 5 FU, and cetuximab (Extreme protocol), the docetaxel combination is considered the therapeutic standard in the first-line palliative treatment of fit patients whose HNSCC lack PD-L1 expression [47]. Furthermore, the compound is effective as monotherapy in second-line therapy or in combination with the EGFR antibody cetuximab. Severe adverse effects (grade 3/4) include infection, nail dystrophy, taste disturbance, stomatitis, and diarrhea. Burdensome adverse effects (grade 2) include alopecia. Particularly distressing is polyneuropathy, which may be irreversible. Common side effects such as nausea/vomiting and allergic reactions can be prevented by adequate supportive therapy.

#### **6.2.3.6 Methotrexate**

Methotrexate can be used as monotherapy, when platinum-based chemotherapy is contraindicated, and results in a remission rate of 3.9% with a median overall survival of 6.7 months compared with gefitinib (40 mg/m<sup>2</sup> weekly) in a randomized phase III trial of [59]. Side effects with MTX were predominantly mucositis, nausea, and constipation.

#### **6.2.3.7 Mitomycin C**

Mitomycin belongs to the group of alkylating antibiotics with antiproliferative activity. In the ARO 95-06 trial, mitomycin was administered together with 5-FU and hyperfractionated radiation compared with radiation therapy alone. After a median follow-up of 8.7 years, local tumor control was 12% higher than the control rate for radiotherapy alone. Mitomycin C/5-FU can thus be used concomitantly to radiation therapy as an alternative to cis- or carboplatin in the presence of contraindications [23].

#### **6.2.3.8 Nivolumab**

Nivolumab is a checkpoint inhibitor that binds to PD-1 and has been evaluated in previously treated HNSCC. The Checkmate-141 phase III study evaluated nivolumab against

"investigator's choice" (methotrexate, docetaxel, or cetuximab) in 361 platinum-refractory patients. Overall survival with nivolumab was 7.7 months vs. 5.1 months, and there was a 1-year survival rate of 34% vs. 19.7% in the control arm. The response rate (ORR) was 13.3 vs. 5.8%. In an exploratory preplanned analysis, overall survival was shown to be dependent on PD-L1 expression  $\geq 1$  (8.7 vs. 4.6 months). The survival benefit could not be demonstrated in patients whose HNSCC did not express PD-L1 [49]. Quality-of-life studies showed that no worsening occurred with nivolumab compared with the control arm [60]. Based on the study results, nivolumab was approved in Europe for platinum-pretreated HNSCC patients.

### **6.2.3.9 Paclitaxel/nab-paclitaxel**

Paclitaxel, like docetaxel, is one of the active agents in HNSCC. Paclitaxel has been studied in combination with platinum and cetuximab in first-line palliative and second-line setting. The CSPOR-HN02 and CETMET trials investigated the role of paclitaxel in first-line palliative therapy. Both trials included only a small number of patients. Effectiveness was comparable to that of other combinations with 5-FU or docetaxel in combination with platinum derivatives. In the advanced tumor setting, Hitt et al. studied a well-tolerated regimen of paclitaxel 80 mg/m<sup>2</sup> weekly in combination with cetuximab in 46 patients, demonstrating an ORR of 54%, a PFS of 4.2 months and an OS of 8.1 months.

For cremophor-free albumin-linked nab-paclitaxel, only one small phase II trial (CACTUX) is available to date, which showed a high ORR of 63%, a PFS of 6.8 months and an OS of 18.8 months.

### **6.2.3.10 Pembrolizumab**

Pembrolizumab is an immune checkpoint inhibitor binding to PD-1, which was evaluated for first-line palliative therapy in the Keynote-048 trial and in advanced disease in Keynote-040. In Keynote-048 (882 patients, phase III), the combination of pembrolizumab with cisplatin and 5-FU was compared to the standard of care cisplatin, 5-FU and cetuximab (PFC; EXTREME regimen). Furthermore, the comparison of pembrolizumab as monotherapy versus PFC was performed. Comparison of the two arms with checkpoint inhibitor was not performed in the 3-arm study. PD-L1 expression was determined by CPS.

The study demonstrated prolonged overall survival compared with the control arm with chemotherapy (median 13.0 vs. 10.7 months, 2-year survival 29% vs. 19%, HR 0.77, 95% CI 0.63-0.93). The effect of immunotherapy added to chemotherapy was particularly evident in the PD-L1 positive population: CPS  $\geq 20$  (median overall survival 14.7 vs. 11.0 months, 2-year survival 35% vs. 19%, HR 0.60; 95% CI 0.45-0.82) and CPS  $\geq 1$  (median 13.6 vs. 10.4 months, 2-year survival 31% vs. 17%, HR 0.65, 95% CI 0.53-0.80).

Pembrolizumab monotherapy compared with the chemotherapy combination PFC showed superior overall survival, but lower response (17% vs. 36%) and poorer progression-free survival (2.3 months vs. 5.2 months, HR 1.34; 95% CI 1.13-1.59) - in subgroups with CPS  $\geq 20$  (PFS median 14.9 vs. 10.7 months, 2-year survival 38% vs. 22%, HR 0.61; 95% CI 0.45-0.83) and with CPS  $\geq 1$  (PFS median 12.3 vs. 10.3 months, 2-year survival 30% vs. 19%, HR 0.78; 95% CI 0.64-0.96)

Data from the Keynote-048 trial led to the approval of pembrolizumab with or without chemotherapy for first-line treatment in patients with CPS  $\geq 1$ .

Pembrolizumab was previously evaluated in a patient population with platinum-refractory head and neck tumors in comparison to "investigator's choice" (cetuximab, docetaxel, or methotrexate) in the Keynote-040 trial. Pembrolizumab prolonged survival (1-year survival 37 vs. 27%,

median overall survival 8.4 vs. 6.9 months, HR 0.80; 95% CI 0.65-0.98). The survival benefit was particularly strong in patients with PD-L1 high-expressing tumors (HR 0.53; 95% CI 0.35-0.81), as determined by TPS. Based on these data, pembrolizumab was approved for pre-treated patients with a PD-L1 TPS  $\geq$ 50% [46, 50].

## 6.3 Special situations

### 6.3.1 Bone metastases

Bone metastases occur with a frequency between 2% and 22% depending on the primary tumor location and may lead to bone fractures, spinal cord compression or hypercalcemia in 27%. Hypercalcemia, due to the secretion of parathyroid related peptide (PTHrP) frequently observed in squamous cell carcinoma, is the most common complication. Patients with bone metastases have a very unfavorable median survival of only 6 months, with the use of radiotherapy and bisphosphonates favorably affecting survival. Therefore, it is recommended to start antiresorptive therapy when bone metastases are detected and to combine it with radiotherapy in symptomatic patients [62].

## 7 Rehabilitation

Head and neck tumors by themselves, but also their treatment by means of surgery, systemic anticancer therapy and/or radiotherapy, often lead to considerable stress, a loss of quality of life, and functional and somatic sequelae such as post-therapeutic chewing, speaking and swallowing disorders or radiation-induced xerostomia, weight loss up to tumor cachexia, chemotherapy-induced polyneuropathy and general weakness up to a (chronic) fatigue syndrome. As a result of these side effects, corresponding comorbidities (e.g., alcohol abuse) and the oncological diagnosis itself, there is a high psychological burden and corresponding need for psycho-oncological and psychosocial care. Therefore, targeted rehabilitation measures are necessary. These should take place as soon as possible after completion of the primary therapy. During rehabilitation, in addition to the general therapy offers (sports/physio-/ergotherapy), comprehensive nutritional counseling and nutritional support should be provided, patients should be included in a teaching kitchen, and there should be the possibility of administering all scientifically recognized forms of nutrition - from normal whole food, enteral nutrition to complete parenteral nutrition. In Germany, the costs of dental rehabilitation with dental implants after therapy of HNSCC are mostly covered by the insurance companies (§28 SGB V). Rehabilitation facilities should be able to continue medical tumor therapies, if indicated. Patients who have not yet reached the statutory retirement age should be informed about services for participation in working life within the framework of medical-occupational oriented rehabilitation (MBOR). Further socio-medical questions as well as any other required patient care should be clarified during rehabilitation. Furthermore, every patient should be offered psycho-oncological care.

## 8 Follow-up

After curative treatment, structured follow-up is required to detect early recurrences or second malignancies and to detect long-term toxicities. The majority of recurrences occur within the first two years after primary therapy. Clinical follow-up is scheduled every 3 months during years 1 and 2, and every 6 months in years 3 to 5. For locally advanced tumors, cross-sectional imaging to check for local recurrence and to eventually detect second tumors is recommended: CT or MRI at 6-month intervals during the first two years and then every 12 months until the fifth year. PET-CT is (still) reserved for special questions and patients after curative RCT in order to decide on neck dissection in case of positive lymph nodes. In addition, cross-sectional imag-

ing should be considered in case of clinical complaints or abnormal clinical examination findings [63].

## 9 References

1. Jansen L, Moratin J, Waldmann A et al. Oral cavity and pharyngeal carcinomas: incidence, mortality, and survival in Germany. *Bundesgesundheitsblatt Health Research Health Protection*. 2021;64(8):941-950. DOI:10.1007/s00103-021-03368-z
2. Tinhofer I, Johrens K, Keilholz U et al. Contribution of human papilloma virus to the incidence of squamous cell carcinoma of the head and neck in a European population with high smoking prevalence. *Eur J Cancer*. 2015;51(4):514-521. DOI:10.1016/j.ejca.2014.12.018
3. Gillison ML, Zhang Q, Jordan R et al. Tobacco smoking and increased risk of death and progression for patients with p16-positive and p16-negative oropharyngeal cancer. *J Clin Oncol*. 2012;30(17):2102-2111. DOI:10.1200/JCO.2011.38.4099
4. Leemans CR, Snijders PJF, Brakenhoff RH. The molecular landscape of head and neck cancer. *Nat Rev Cancer*. 2018;18(5):269-282. DOI:10.1038/nrc.2018.11
5. De Stefani E, Boffetta P, Oreggia F, Fierro L, Mendilaharsu M. Hard liquor drinking is associated with higher risk of cancer of the oral cavity and pharynx than wine drinking. A case-control study in Uruguay. *Oral Oncol*. 1998;34(2):99-104. DOI:10.1016/S1368-8375(97)00062-6
6. Wyss A, Hashibe M, Chuang SC et al. Cigarette, cigar, and pipe smoking and the risk of head and neck cancers: pooled analysis in the International Head and Neck Cancer Epidemiology Consortium. *Am J Epidemiol*. 2013;178(5):679-690. DOI:10.1093/aje/kwt029
7. Blot WJ, McLaughlin JK, Winn DM et al. Smoking and drinking in relation to oral and pharyngeal cancer. *Cancer Res*. 1988;48(11):3282-3287. PMID:3365707
8. Spitz MR. Epidemiology and risk factors for head and neck cancer. *Semin Oncol*. 1994;21(3):281-288. PMID:8209260
9. Chaturvedi AK, Engels EA, Pfeiffer RM et al. Human papillomavirus and rising oropharyngeal cancer incidence in the United States. *J Clin Oncol*. 2011;29(32):4294-4301. DOI:10.1200/JCO.2011.36.4596
10. Hashim D, Sartori S, Brennan P et al. The role of oral hygiene in head and neck cancer: results from International Head and Neck Cancer Epidemiology (INHANCE) consortium. *Ann Oncol*. 2016;27(8):1619-1625. DOI:10.1093/annonc/mdw224
11. Mahale P, Sturgis EM, Tweardy DJ, Ariza-Heredia EJ, Torres HA. Association between hepatitis C virus and head and neck cancers. *J Natl Cancer Inst*. 2016;108(8):djw035. DOI:10.1093/jnci/djw035
12. Vaccarezza GF, Antunes JL, Michaluart-Junior P. Recurrent sores by ill-fitting dentures and intra-oral squamous cell carcinoma in smokers. *J Public Health Dent*. 2010;70(1):52-57. DOI:10.1111/j.1752-7325.2009.00143.x
13. Guha N, Warnakulasuriya S, Vlaanderen J, Straif K. Betel quid chewing and the risk of oral and oropharyngeal cancers: a meta-analysis with implications for cancer control. *Int J Cancer*. 2014;135(6):1433-1443. DOI:10.1002/ijc.28643
14. Vukovic V, Stojanovic J, Vecchioni A, Pastorino R, Boccia S. Systematic review and meta-analysis of SNPs from genome-wide association studies of head and neck cancer. *Otolaryngol Head Neck Surg*. 2018;159(4):615-624. DOI:10.1177/0194599818792262
15. Rabinovics N, Mizrachi A, Hadar T et al. Cancer of the head and neck region in solid organ transplant recipients. *Head Neck*. 2014;36(2):181-186. DOI:10.1002/hed.23283

16. Lewin F, Norell SE, Johansson H et al. Smoking tobacco, oral snuff, and alcohol in the etiology of squamous cell carcinoma of the head and neck: a population-based case-referent study in Sweden. *Cancer*. 1998;82(7):1367-1375. DOI:[10.1002/\(sici\)1097-0142\(19980401\)82:7<1367::aid-cncr21>3.0.co;2-3](https://doi.org/10.1002/(sici)1097-0142(19980401)82:7<1367::aid-cncr21>3.0.co;2-3)
17. Mehanna H, Wong WL, McConkey CC et al. PET-CT surveillance versus neck dissection in advanced head and neck cancer. *N Engl J Med*. 2016;374(15):1444-1454. DOI:[10.1056/NEJMoa1514493](https://doi.org/10.1056/NEJMoa1514493)
18. Zhong J, Sundersingh M, Dyker K et al. Post-treatment FDG PET-CT in head and neck carcinoma: comparative analysis of 4 qualitative interpretative criteria in a large patient cohort. *Sci Rep*. 2020;10(1):4086. DOI:[10.1038/s41598-020-60739-3](https://doi.org/10.1038/s41598-020-60739-3)
19. Hermanns I, Ziadat R, Schlattmann P, Guntinas-Lichius O. Trends in treatment of head and neck cancer in Germany: a Diagnosis-Related-Groups-based nationwide analysis, 2005-2018. *Cancers (Basel)*. 2021;13(23):6060. DOI:[10.3390/cancers13236060](https://doi.org/10.3390/cancers13236060)
20. Forastiere AA, Ismaila N, Lewin JS et al. Use of laryngeal preservation strategies in the treatment of laryngeal cancer: American Society of Clinical Oncology clinical practice guideline update. *J Clin Oncol*. 2018;36(11):1143-1169. DOI:[10.1200/JCO.2017.75.7385](https://doi.org/10.1200/JCO.2017.75.7385)
21. Pignon JP, le Maitre A, Maillard E, Bourhis J. Meta-analysis of chemotherapy in head and neck cancer (MACH-NC): an update on 93 randomised trials and 17,346 patients. *Radiother Oncol*. 2009;92(1):4-14. DOI:[10.1016/j.radonc.2009.04.014](https://doi.org/10.1016/j.radonc.2009.04.014)
22. Amini A, Jones BL, McDermott JD et al. Survival outcomes with concurrent chemoradiation for elderly patients with locally advanced head and neck cancer according to the National Cancer Data Base. *Cancer*. 2016;122(10):1533-1543. DOI:[10.1002/cncr.29956](https://doi.org/10.1002/cncr.29956)
23. Budach V, Stromberger C, Poettgen C et al. Hyperfractionated accelerated radiation therapy (HART) of 70.6 Gy with concurrent 5-FU/mitomycin C is superior to HART of 77.6 Gy alone in locally advanced head and neck cancer: long-term results of the ARO 95-06 randomized phase III trial. *Int J Radiat Oncol Biol Phys*. 2015;91(5):916-924. DOI:[10.1016/j.ijrobp.2014.12.034](https://doi.org/10.1016/j.ijrobp.2014.12.034)
24. Bonner JA, Harari PM, Giralt J et al. Radiotherapy plus cetuximab for squamous-cell carcinoma of the head and neck. *N Engl J Med*. 2006;354(6):567-578. DOI:[10.1056/NEJMoa053422](https://doi.org/10.1056/NEJMoa053422)
25. Rischin D, King M, Kenny L et al. Randomized trial of radiation therapy with weekly cisplatin or cetuximab in low-risk HPV-associated oropharyngeal cancer (TROG 12.01) - a Trans-Tasman Radiation Oncology Group study. *Int J Radiat Oncol Biol Phys*. 2021;111(4):876-886. DOI:[10.1016/j.ijrobp.2021.04.015](https://doi.org/10.1016/j.ijrobp.2021.04.015)
26. Gebre-Medhin M, Brun E, Engstrom P et al. ARTSCAN III: a randomized phase III study comparing chemoradiotherapy with cisplatin versus cetuximab in patients with locoregionally advanced head and neck squamous cell cancer. *J Clin Oncol*. 2021;39(1):38-47. DOI:[10.1200/JCO.20.02072](https://doi.org/10.1200/JCO.20.02072)
27. Petrelli F, Coinu A, Riboldi V et al. Concomitant platinum-based chemotherapy or cetuximab with radiotherapy for locally advanced head and neck cancer: a systematic review and meta-analysis of published studies. *Oral Oncol*. 2014;50(11):1041-1048. DOI:[10.1016/j.oraloncology.2014.08.005](https://doi.org/10.1016/j.oraloncology.2014.08.005)
28. Tang WH, Sun W, Long GX. Concurrent cisplatin or cetuximab with radiotherapy in patients with locally advanced head and neck squamous cell carcinoma: A meta-analysis. *Medicine (Baltimore)*. 2020;99(36):e21785. DOI:[10.1097/MD.00000000000021785](https://doi.org/10.1097/MD.00000000000021785)
29. Blanchard P, Baujat B, Holostenco V et al. Meta-analysis of chemotherapy in head and neck cancer (MACH-NC): a comprehensive analysis by tumor site. *Radiother Oncol*. 2011;100(1):33-40. DOI:[10.1016/j.radonc.2011.05.036](https://doi.org/10.1016/j.radonc.2011.05.036)

30. Sharma A, Kumar M, Bhasker S et al. An open-label, noninferiority phase III RCT of weekly versus three weekly cisplatin and radical radiotherapy in locally advanced head and neck squamous cell carcinoma (ConCERT trial). *J Clin Oncol.* 2022;40(16\_suppl):6004. DOI:10.1200/JCO.2022.40.16\_suppl.6004
31. Szturz P, Wouters K, Kiyota N et al. Weekly low-dose versus three-weekly high-dose cisplatin for concurrent chemoradiation in locoregionally advanced non-nasopharyngeal head and neck cancer: a systematic review and meta-analysis of aggregate data. *Oncologist.* 2017;22(9):1056-1066. DOI:10.1634/theoncologist.2017-0015
32. Mehanna H, Robinson M, Hartley A et al. Radiotherapy plus cisplatin or cetuximab in low-risk human papillomavirus-positive oropharyngeal cancer (De-ESCALaTE HPV): an open-label randomised controlled phase 3 trial. *Lancet.* 2019;393(10166):51-60. DOI:10.1016/S0140-6736(18)32752-1
33. Gillison ML, Trotti AM, Harris J et al. Radiotherapy plus cetuximab or cisplatin in human papillomavirus-positive oropharyngeal cancer (NRG Oncology RTOG 1016): a randomised, multicentre, non-inferiority trial. *Lancet.* 2019;393(10166):40-50. DOI:10.1016/S0140-6736(18)32779-X
34. Bourhis J, Tao Y, Sun X et al. Avelumab-cetuximab-radiotherapy versus standards of care in patients with locally advanced squamous cell carcinoma of head and neck (LA-SCCHN): Randomized phase III GORTEC-REACH trial. *Ann Oncol.* 2021;32:S1283. DOI:10.1016/j.annonc.2021.08.2112
35. Bourhis J, Sine C, Tao Y et al. Pembrolizumab versus cetuximab, concomitant with radiotherapy (RT) in locally advanced head and neck squamous cell carcinoma (LA-HNSCC): Results of the GORTEC 2015-01 "PembroRad" randomized trial. *Ann Oncol.* 2020;31:S1168. DOI:10.1016/j.annonc.2020.08.2268
36. Lee NY, Ferris RL, Psyrri A et al. Avelumab plus standard-of-care chemoradiotherapy versus chemoradiotherapy alone in patients with locally advanced squamous cell carcinoma of the head and neck: a randomised, double-blind, placebo-controlled, multicentre, phase 3 trial. *Lancet Oncol.* 2021;22(4):450-462. DOI:10.1016/S1470-2045(20)30737-3
37. Kiyota N, Tahara M, Mizusawa J et al. Weekly cisplatin plus radiation for postoperative head and neck cancer (JCOG1008): a multicenter, noninferiority, phase II/III randomized controlled trial. *J Clin Oncol.* 2022;40(18):1980-1990. DOI:10.1200/JCO.21.01293
38. Lacas B, Carmel A, Landais C et al. Meta-analysis of chemotherapy in head and neck cancer (MACH-NC): An update on 107 randomized trials and 19,805 patients, on behalf of MACH-NC Group. *Radiother Oncol.* 2021;156:281-293. DOI:10.1016/j.radonc.2021.01.013
39. Stell PM, Rawson NS. Adjuvant chemotherapy in head and neck cancer. *Br J Cancer.* 1990;61(5):779-787. DOI:10.1038/bjc.1990.175
40. Ma J, Liu Y, Huang XL et al. Induction chemotherapy decreases the rate of distant metastasis in patients with head and neck squamous cell carcinoma but does not improve survival or locoregional control: a meta-analysis. *Oral Oncol.* 2012;48(11):1076-1084. DOI:10.1016/j.oraloncology.2012.06.014
41. Budach W, Bolke E, Kammers K et al. Induction chemotherapy followed by concurrent radio-chemotherapy versus concurrent radio-chemotherapy alone as treatment of locally advanced squamous cell carcinoma of the head and neck (HNSCC): A meta-analysis of randomized trials. *Radiother Oncol.* 2016;118(2):238-243. DOI:10.1016/j.radonc.2015.10.014
42. Forastiere AA, Zhang Q, Weber RS et al. Long-term results of RTOG 91-11: a comparison of three nonsurgical treatment strategies to preserve the larynx in patients with locally advanced laryngeal cancer. *J Clin Oncol.* 2013;31(7):845-852. DOI:10.1200/JCO.2012.43.6097

43. Vermorken JB, Remenar E, van Herpen C et al. Cisplatin, fluorouracil, and docetaxel in unresectable head and neck cancer. *N Engl J Med*. 2007;357(17):1695-1704. DOI:10.1056/NEJMoa071028
44. Dietz A, Wichmann G, Kuhnt T et al. Induction chemotherapy (IC) followed by radiotherapy (RT) versus cetuximab plus IC and RT in advanced laryngeal/hypopharyngeal cancer resectable only by total laryngectomy-final results of the laryngeal organ preservation trial DeLOS-II. *Ann Oncol*. 2018;29(10):2105-2114. DOI:10.1093/annonc/mdy332
45. Oncology guideline program (German Cancer Society, German Cancer Aid, AWMF): Diagnostics, therapy and follow-up of laryngeal carcinoma, long version 1.1, 2019, AWMF register number: 017/076OL, <http://www.leitlinienprogrammonkologie.de/leitlinien/larynxkarzinom/> (retrieved on: 09/30/2022).
46. Burtneß B, Harrington KJ, Greil R et al. Pembrolizumab alone or with chemotherapy versus cetuximab with chemotherapy for recurrent or metastatic squamous cell carcinoma of the head and neck (KEYNOTE-048): a randomised, open-label, phase 3 study. *Lancet*. 2019;394(10212):1915-1928. DOI:10.1016/S0140-6736(19)32591-7
47. Guigay J, Auperin A, Fayette J et al. Cetuximab, docetaxel, and cisplatin versus platinum, fluorouracil, and cetuximab as first-line treatment in patients with recurrent or metastatic head and neck squamous-cell carcinoma (GORTEC 2014-01 TPEXtreme): a multicentre, open-label, randomised, phase 2 trial. *Lancet Oncol*. 2021;22(4):463-475. DOI:10.1016/S1470-2045(20)30755-5
48. Vermorken JB, Mesia R, Rivera F et al. Platinum-based chemotherapy plus cetuximab in head and neck cancer. *N Engl J Med*. 2008;359(11):1116-1127. DOI:10.1056/NEJMoa0802656
49. Ferris RL, Blumenschein G, Jr, Fayette J et al. Nivolumab for Recurrent Squamous-Cell Carcinoma of the Head and Neck. *N Engl J Med*. 2016;375(19):1856-1867. DOI:10.1056/NEJMoa1602252
50. Cohen EEW, Soulieres D, Le Tourneau C et al. Pembrolizumab versus methotrexate, docetaxel, or cetuximab for recurrent or metastatic head-and-neck squamous cell carcinoma (KEYNOTE-040): a randomised, open-label, phase 3 study. *Lancet*. 2019;393(10167):156-167. DOI:10.1016/S0140-6736(18)31999-8
51. Saleh K, Daste A, Martin N et al. Response to salvage chemotherapy after progression on immune checkpoint inhibitors in patients with recurrent and/or metastatic squamous cell carcinoma of the head and neck. *Eur J Cancer*. 2019;121:123-129. DOI:10.1016/j.ejca.2019.08.026
52. Guigay J, Auperin A, Mertens C et al. Personalized treatment according to geriatric assessment in first-line recurrent and/or metastatic (R/M) head and neck squamous cell cancer (HNSCC) patients aged 70 or over: ELAN (ELderly heAd and Neck cancer) FIT and UNFIT trials. *Ann Oncol*. 2020;30 (Suppl\_5):V450. DOI:10.1093/annonc/mdz252.002
53. Bonner JA, Harari PM, Giralt J et al. Radiotherapy plus cetuximab for locoregionally advanced head and neck cancer: 5-year survival data from a phase 3 randomised trial, and relation between cetuximab-induced rash and survival. *Lancet Oncol*. 2010;11(1):21-28. DOI:10.1016/S1470-2045(09)70311-0
54. Ang KK, Zhang Q, Rosenthal DI et al. Randomized phase III trial of concurrent accelerated radiation plus cisplatin with or without cetuximab for stage III to IV head and neck carcinoma: RTOG 0522. *J Clin Oncol*. 2014;32(27):2940-2950. DOI:10.1200/JCO.2013.53.5633
55. Mohamed A, Twardy B, Zordok MA et al. Concurrent chemoradiotherapy with weekly versus triweekly cisplatin in locally advanced squamous cell carcinoma of the head and neck: comparative analysis. *Head Neck*. 2019;41(5):1490-1498. DOI:10.1002/hed.25379

56. Guardiola E, Peyrade F, Chaigneau L et al. Results of a randomised phase II study comparing docetaxel with methotrexate in patients with recurrent head and neck cancer. *Eur J Cancer*. 2004;40(14):2071-2076. [DOI:10.1016/j.ejca.2004.05.019](https://doi.org/10.1016/j.ejca.2004.05.019)
57. Catimel G, Verweij J, Mattijssen V et al. Docetaxel (Taxotere): an active drug for the treatment of patients with advanced squamous cell carcinoma of the head and neck. EORTC Early Clinical Trials Group. *Ann Oncol*. 1994;5(6):533-537. [DOI:10.1093/oxfordjournals.annonc.a058908](https://doi.org/10.1093/oxfordjournals.annonc.a058908)
58. Knoedler M, Gauler TC, Gruenwald V et al. Phase II study of cetuximab in combination with docetaxel in patients with recurrent and/or metastatic squamous cell carcinoma of the head and neck after platinum-containing therapy: a multicenter study of the Arbeitsgemeinschaft Internistische Onkologie. *Oncology*. 2013;84(5):284-289. [DOI:10.1159/000345453](https://doi.org/10.1159/000345453)
59. Stewart JSW, Cohen EE, Licitra L et al. Phase III study of gefitinib compared with intravenous methotrexate for recurrent squamous cell carcinoma of the head and neck [corrected]. *J Clin Oncol*. 2009;27(11):1864-1871. [DOI:10.1200/JCO.2008.17.0530](https://doi.org/10.1200/JCO.2008.17.0530)
60. Harrington KJ, Ferris RL, Blumenschein G Jr et al. Nivolumab versus standard, single-agent therapy of investigator's choice in recurrent or metastatic squamous cell carcinoma of the head and neck (CheckMate 141): health-related quality-of-life results from a randomised, phase 3 trial. *Lancet Oncol*. 2017;18(8):1104-1115. [DOI:10.1016/S1470-2045\(17\)30421-7](https://doi.org/10.1016/S1470-2045(17)30421-7)
61. Forastiere AA, Shank D, Neuberg D, Taylor SG 4th, DeConti RC, Adams G. Final report of a phase II evaluation of paclitaxel in patients with advanced squamous cell carcinoma of the head and neck: an Eastern Cooperative Oncology Group trial (PA390). *Cancer*. 1998;82(11):2270-2274. [PMID:9610709](https://pubmed.ncbi.nlm.nih.gov/9610709/)
62. Grisanti S, Bianchi S, Locati LD et al. Bone metastases from head and neck malignancies: prognostic factors and skeletal-related events. *PLoS One*. 2019;14(3):e0213934. [DOI:10.1371/journal.pone.0213934](https://doi.org/10.1371/journal.pone.0213934)
63. Machiels JP, René Leemans C, Golusinski W et al. Squamous cell carcinoma of the oral cavity, larynx, oropharynx and hypopharynx: EHNS-ESMO-ESTRO clinical practice guidelines for diagnosis, treatment and follow-up. *Ann Oncol*. 2020;31(11):1462-1475. [DOI:10.1016/j.annonc.2020.07.011](https://doi.org/10.1016/j.annonc.2020.07.011)

## 10 Authors' Affiliations

### **PD Dr. med. Melanie Boxberg**

Technische Universität München  
 Institut für Pathologie  
 Trogerstr. 18  
 81675 München  
[melanie.boxberg@tum.de](mailto:melanie.boxberg@tum.de)

### **Prof. Dr. med. Peter Brossart**

Universitätsklinikum Bonn  
 Medizinische Klinik III  
 Onkologie und Hämatologie  
 Sigmund-Freud-Str. 25  
 53105 Bonn  
[peter.brossart@ukb.uni-bonn.de](mailto:peter.brossart@ukb.uni-bonn.de)

**Prof. Dr. med. Wilfried Budach**

Universitätsklinikum Düsseldorf  
Klinik für Strahlentherapie und Radioonkologie  
Moorenstrasse 5  
40225 Düsseldorf  
[wilfried.budach@med.uni-duesseldorf.de](mailto:wilfried.budach@med.uni-duesseldorf.de)

**Prof. Dr. med. Andreas Dietz**

Universitätsklinikum Leipzig  
Klinik und Poliklinik für Hals-, Nasen-, Ohrenheilkunde  
Liebigstrasse 10-14  
04103 Leipzig  
[andreas.dietz@medizin.uni-leipzig.de](mailto:andreas.dietz@medizin.uni-leipzig.de)

**Prof. Dr. med. Michael Flentje**

Universitätsklinikum Würzburg  
Klinik und Poliklinik für Strahlentherapie  
Josef-Schneider-Str. 11  
97080 Würzburg  
[flentje\\_m@ukw.de](mailto:flentje_m@ukw.de)

**Prof. Dr. med. Viktor Grünwald**

Universitätsklinikum Essen  
Innere Klinik  
Tumorforschung  
Hufelandstr. 55  
45147 Essen  
[Viktor.Gruenwald@uk-essen.de](mailto:Viktor.Gruenwald@uk-essen.de)

**Prof. Dr. med. Orlando Guntinas-Lichius**

Universitätsklinikum Jena  
Klinik für Hals-, Nasen- und Ohrenheilkunde  
Kastanienstr. 1  
07747 Jena  
[orlando.Guntinas@med.uni-jena.de](mailto:orlando.Guntinas@med.uni-jena.de)

**Dr. Dennis Hahn**

Katharinenhospital Stuttgart  
Klinik für Hämatologie und Onkologie  
Kriegsbergstr. 60  
70174 Stuttgart  
[d.hahn@klinikum-stuttgart.de](mailto:d.hahn@klinikum-stuttgart.de)

**Prof. Dr. Dr. med. Max Heiland**

Charité Universitätsmedizin Berlin  
Klinik für Mund-, Kiefer- und Gesichtschirurgie  
Augustenburger Platz 1  
13353 Berlin  
[max.heiland@charite.de](mailto:max.heiland@charite.de)

**Prof. Dr. Korinna Jöhrens**

Universitätsklinikum Carl Gustav Carus  
Institut für Pathologie  
Fetscherstr. 74  
01307 Dresden  
[Korinna.Joehrens@uniklinikum-dresden.de](mailto:Korinna.Joehrens@uniklinikum-dresden.de)

**PD Dr. med. Konrad Klinghammer**

Charité Universitätsmedizin Berlin  
Medizinische Klinik mit Schwerpunkt Hämatologie,  
Onkologie und Tumorummunologie (CBF)  
Hindenburgdamm 30  
12203 Berlin  
[konrad.klinghammer@charite.de](mailto:konrad.klinghammer@charite.de)

**Dr. med. Maren Knödler**

Charité Universitätsmedizin Berlin  
Campus Mitte  
Charité Centrum für Multidisziplinäre Medizin  
Charitéplatz 1  
10117 Berlin  
[maren.knoedler@charite.de](mailto:maren.knoedler@charite.de)

**Dr. med. Florian Kocher**

Medizinische Universität Innsbruck  
Universitätsklinik für Innere Medizin V  
Anichstr. 35  
A-6020 Innsbruck  
[florian.kocher@i-med.ac.at](mailto:florian.kocher@i-med.ac.at)

**Prof. Dr. med. Georg Maschmeyer**

Deutsche Gesellschaft für Hämatologie  
und Medizinische Onkologie (DGHO)  
Onkopedia-Koordinator  
Bauhofstr. 12  
10117 Berlin  
[maschmeyer@dgho.de](mailto:maschmeyer@dgho.de)

**Prof. Dr. med. Dr. phil. Sacha Rothschild**

Zentrum Onkologie / Hämatologie  
Kantonsspital Baden AG  
Im Ergel 1  
CH-5404 Baden  
[Sacha.Rothschild@ksb.ch](mailto:Sacha.Rothschild@ksb.ch)

**Prof. Dr. med. Bernhard Wörmann**

Amb. Gesundheitszentrum der Charité  
Campus Virchow-Klinikum  
Med. Klinik m.S. Hämatologie & Onkologie  
Augustenburger Platz 1  
13344 Berlin  
[bernhard.woermann@charite.de](mailto:bernhard.woermann@charite.de)

## **11 Disclosures**

according to the [rules of DGHO, OeGHO, SGH+SSH, SGM0](#)

Author	Employer <sup>1</sup>	Consulting / Expert opinion <sup>2</sup>	Shares / Funds <sup>3</sup>	Patent / Copyright / License <sup>4</sup>	Fees <sup>5</sup>	Funding of scientific research <sup>6</sup>	Other financial relations <sup>7</sup>	Personal relationship with authorized representatives <sup>8</sup>
Boxberg, Melanie	Pathologie München Nord Ernst-Platz Str.2 80992 München Institut für Pathologie der TU München Trogerstr. 18 81675 München	<b>Yes</b> Advisoryboards von BMS/MSD	<b>No</b>	<b>No</b>	<b>No</b>	<b>Yes</b> Drittmittel von BMS	<b>No</b>	<b>No</b>
Brossart, Peter	Universitätsklinikum Bonn	<b>Yes</b> BMS, AMGEN, AstraZeneca	<b>No</b>	<b>No</b>	<b>Yes</b> BMS,AstraZeneca	<b>Yes</b> BMS	<b>Yes</b> Gilead, BMS	<b>No</b>
Budach, Wilfried	Universitätsklinikum Düsseldorf	<b>Yes</b> Advisory Board: MSD, Merck, Pfizer, BMS	<b>No</b>	<b>No</b>	<b>Yes</b> med publico GmbH; MSD; Merck; Jörg Eickeler Beratung, Düsseldorf; Deutsche Akademie für Senologie	<b>No</b>	<b>No</b>	<b>No</b>
Dietz, Andreas	Universitätsklinikum Leipzig	<b>No</b>	<b>No</b>	<b>No</b>	<b>Yes</b> Vortragshonorare MSD, Sanofi, Sun,	<b>No</b>	<b>No</b>	<b>No</b>
Flentje, Michael	Klinikum der Universität Würzburg	<b>No</b>	<b>No</b>	<b>No</b>	<b>No</b>	<b>No</b>	<b>No</b>	<b>No</b>
Grünwald, Viktor	Uniklinik Essen	<b>Yes</b> Apogepha BMS Cureteq Debiopharm EISAI EUSA Pharm Merck Serono MSD Oncorena PCI Biotech Pfizer Pfizer Roche	<b>Yes</b> Astrazeneca, BMS, MSD, Seagen	<b>No</b>	<b>Yes</b> Amgen Astellas AstraZeneca BMS EISAI Ipsen Janssen-Cilag Merck Serono MSD Novartis Pfizer	<b>Yes</b> Astrazeneca BMS Ipsen MSD Pfizer	<b>Yes</b> Ipsen, Reisekosten Janssen Cilag, Reisekosten Merck Serono, Reisekosten Pfizer, Reisekosten	<b>No</b>
Guntinas-Lichius, Orlando	Universitätsklinikum Jena	<b>Yes</b> Advisory Merz Pharma Novartis MEDICE	<b>No</b>	<b>No</b>	<b>Yes</b> Sanofi Aventis Merck Merz Pharma MED-EL Novartis MEDICE	<b>Yes</b> Forschungsvorhaben mit MED-EL, Innsbruck	<b>No</b>	<b>No</b>
Hahn, Dennis	Klinikum Stuttgart Klinik für Hämatologie, internist. Onkologie, Palliativmedizin und Stammzelltransplantation	<b>Yes</b> BMS, Merck, MSD, Takeda	<b>No</b>	<b>No</b>	<b>Yes</b> BMS, Merck, MSD, Takeda	<b>No</b>	<b>No</b>	<b>No</b>
Heiland, Max	Charité Universitätsmedizin Berlin Klinik für Mund-, Kiefer- und Gesichtschirurgie	<b>Yes</b>	<b>No</b>	<b>No</b>	<b>Yes</b>	<b>Yes</b>	<b>No</b>	<b>No</b>

Author	Employer <sup>1</sup>	Consulting / Expert opinion <sup>2</sup>	Shares / Funds <sup>3</sup>	Patent / Copyright / License <sup>4</sup>	Fees <sup>5</sup>	Funding of scientific research <sup>6</sup>	Other financial relations <sup>7</sup>	Personal relationship with authorized representatives <sup>8</sup>
		<p>Tätigkeit als Berater*in bzw. Gutachter*in oder bezahlte Mitarbeit in einem wissenschaftlichen Beirat / Advisory Board eines Unternehmens der Gesundheitswirtschaft (z. B. Arzneimittelin- dustrie, Medizinproduktindustrie), eines kommerziell orientierten Auftragsinstituts oder einer Versicherung type of interest Cooperation partner/source of funding Period of cooperation/activity Thematic scope of the project, reference to the guideline Type of the grant Value of the grant Recipient Consulting/ Honoraria Saudi German Hospital Group From: 01.01.2019 To: 09.06.2022 Consultant MKG Honorar 198.000 persönlich Advisory boards AO Foundation From: 01.07.2021 To: 09.06.2022 Mitglied im AOCMF International Board Aufwand- schädigung 17.000 persönlich Advisory boards Nanobiotix From: 02.04.2019 To: 02.04.2019 Expert Meeting, Advanced Squamous Cell Carcinoma Honorar 400 persönlich Advisory boards Merck Serono From:</p>			<p>Lecture and/or training activities Pfaff Institut der Zahnärztekammer Berlin From:01.01.2019 To: 09.06.2022 Implantatkurse Honorar 9.000 persönlich Lecture and/or training activities KLS Martin From:01.01.2019 To: 09.06.2022 Vorträge zum Thema virtuelle OP-Planung, patienten-spezifische Implantate Honorar 3.900 persönlich Lecture and/or training activities medentis medical GmbH From:01.01.2019 To: 09.06.2022 Implantatkurse, Vorträge Honorar 15.000 persönlich Lecture and/or training activities Norgine From:28.11.2019 To: 29.11.2019 Kurs zur Sentinel Lymphknotenbiopsie Honorar 4.500 persönlich Paid and/or Co-authorship Thieme Verlag From: 01.01.2019 To: 09.06.2022 Herausgeber und Autor Digitale Volumentomographie Honorar 1.000 persönlich</p>	<p>Research grants/ contracts (restricted or unrestricted) KLS Martin From: 01.03.2022 To: 09.06.2022 Translation oberflächenmodifizierter Implantatsysteme Forschungsförderung 1.370.000 institutionell Research grants/contracts (restricted or unrestricted) AO Foundation From: 01.01.2019 To: 13.06.2022 MRONJ Registry Vergütung pro eingeschlossenem Patienten 5.000 institutionell Research grants/contracts (restricted or unrestricted) DFG via Universitätsklinikum Heidelberg From: 01.01.2019 To: 13.06.2022 APOS Studie, nein Vergütung pro eingeschlossenem Patienten 3.500 institutionell</p>		

Author	Employer <sup>1</sup>	Consulting / Expert opinion <sup>2</sup>	Shares / Funds <sup>3</sup>	Patent / Copyright / License <sup>4</sup>	Fees <sup>5</sup>	Funding of scientific research <sup>6</sup>	Other financial relations <sup>7</sup>	Personal relationship with authorized representatives <sup>8</sup>
		06.11.2021 To: 06.11.2021 Expertenmeeting Kopf-Hals-Tumor Honorar 900 persönlich Advisory boards Sanofi From: 14.07.2021 To: 14.07.2021 Expertenmeeting Non-melanoma skin cancer Honorar 800 persönlich						
Jöhrens, Korinna	Carl Gustav Carus Universitätsklinikum Dresden, Institut für Pathologie	<b>Yes</b> MSD, Agilent, EUSA, QuIP	<b>No</b>	<b>No</b>	<b>Yes</b> MSD, Agilent, BMS, EUSA, QuIP, Targos, AstraZeneca	<b>No</b>	<b>No</b>	<b>No</b>
Klinghammer, Konrad	Charité Universitätsmedizin Berlin	<b>Yes</b> -MSD -Merck -BMS -Bayer	<b>No</b>	<b>No</b>	<b>Yes</b> -MSD -Merck -BMS	<b>No</b>	<b>No</b>	<b>No</b>
Knödler, Maren	Aktuell: Charité Universitätsmedizin Berlin CCCC, CCM Bis 8/22 Universitätsklinikum Leipzig, Universitäres Krebszentrum, Med. Klinik I	<b>No</b>	<b>No</b>	<b>No</b>	<b>No</b>	<b>No</b>	<b>No</b>	<b>No</b>
Kocher, Florian	Medizinische Universität Innsbruck	<b>Yes</b> MSD, Merck	<b>No</b>	<b>No</b>	<b>Yes</b> MSD, Merck	<b>No</b>	<b>No</b>	<b>No</b>
Maschmeyer, Georg	Charité Universitätsmedizin Berlin; DGHO (freiberuflich); bis 31.3.2022: Klinikum Ernst von Bergmann Potsdam	<b>No</b>	<b>No</b>	<b>No</b>	<b>Yes</b>	<b>No</b>	<b>No</b>	<b>No</b>

Author	Employer <sup>1</sup>	Consulting / Expert opinion <sup>2</sup>	Shares / Funds <sup>3</sup>	Patent / Copyright / License <sup>4</sup>	Fees <sup>5</sup>	Funding of scientific research <sup>6</sup>	Other financial relations <sup>7</sup>	Personal relationship with authorized representatives <sup>8</sup>
					Gilead Sciences GmbH (Vorträge und Veranstaltungenmoderation Infektionen), Merck-Serono (Moderation Roundtable Kolorektale Karzinome), Bristol-Myers Squibb (Vortrag Thema Immuntherapie von Tumorerkrankungen), AMGEN (Vortrag Thema Infektionen), AstraZeneca (Moderation Thema Immuntherapie von Tumorerkrankungen), Janssen-Cilag (Vortrag Infektionen); medupdate GmbH (Vortrag Neuigkeiten Hämatologie); RG (Vortrag/Moderation Highlights Hämatologie/ Onkologie); FOMF GmbH (Kopf-Hals-Tumoren)			
Rothschild, Sacha	ab 11/2022 Kantonsspital Baden, Zentrum für Onkologie & Hämatologie 07/2011-10/2022 Universitätsspital Basel, Medizinische Onkologie	<b>Yes</b> AbbVie, Amgen, Astellas, Astra-Zeneca, Bayer, BMS, Boehringer-Ingelheim, Eisai, Eli Lilly, Janssen, Merck Serono, MSD, Novartis, Otsuka, Pfizer, PharmaMar, Roche Pharma, Roche Diagnostics, Sanofi, Aventis, Takeda (Bezahlungen an die Institution)	<b>No</b>	<b>No</b>	<b>Yes</b> Amgen, AstraZeneca, BMS, Janssen, MSD Oncology, Novartis, Roche Pharma, Roche Diagnostics, Sanofi, Takeda (Bezahlungen an die Institution)	<b>Yes</b> AbbVie, Amgen, Astra-Zeneca, BMS, Boehringer-Ingelheim, Foundation Medicine, Merck, Roche Pharma	<b>Yes</b> Amgen, AstraZeneca, BMS, Boehringer-Ingelheim, Eli Lilly, MSD, Roche, Takeda (Reise- und Kongresskosten)	<b>No</b>
Wörmann, Bernhard	DGHO, Charité Universitätsmedizin Berlin	<b>No</b>	<b>No</b>	<b>No</b>	<b>No</b>	<b>No</b>	<b>No</b>	<b>No</b>

*Legend:*

<sup>1</sup> - Current employer, relevant previous employers in the last 3 years (institution/location).

<sup>2</sup> - Activity as a consultant or expert or paid participation in a scientific advisory board of a company in the health care industry (e.g., pharmaceutical industry, medical device industry), a commercially oriented contract research organization, or an insurance company.

<sup>3</sup> - Ownership of business shares, stocks, funds with participation of companies of the health care industry.

<sup>4</sup> - Relates to drugs and medical devices.

<sup>5</sup> - Honoraria for lecturing and training activities or paid authors or co-authorships on behalf of a company in the health care industry, a commercially oriented contracting institute or an insurance company.

<sup>6</sup> - Financial support (third-party funds) for research projects or direct financing of employees of the institution by a company in the health care industry, a commercially oriented contract institute or an insurance company.

<sup>7</sup> - Other financial relationships, e.g., gifts, travel reimbursements, or other payments in excess of 100 euros outside of research projects, if paid by an entity that has an investment in, license to, or other commercial interest in the subject matter of the investigation.

<sup>8</sup> - Personal relationship with an authorized representative(s) of a healthcare company.